Portuguese Journal of Dermatology and Venereology

Permanyer

Check for updates

Port J Dermatol and Venereol.

DERMATOLOGY IMAGES

A giant inguinal dermatofibrosarcoma protuberans

Dermatofibrosarcoma protuberante gigante da região inguinal

Patrícia Moreira Gomes[1], Ruben Costa[1], Inês Rodrigues[2], and Filomena Azevedo[1]*

[1]Department of Dermatology and Venereology; [2]Department of Pathology. Unidade Local de Saúde de São João, Porto, Portugal

A 41-year-old male presented with an asymptomatic lesion on his groin that had been gradually enlarging over 5 years. On physical examination, a 12 × 7 cm slightly indurated, flesh-colored plaque with pedunculated nodules was observed in the left inguinal region (Fig. 1). Histopathological examination of a biopsy showed a tumor with diffuse infiltration of the skin and subcutaneous tissue composed of uniform and medium-sized spindle cells with a storiform or cartwheel pattern of growth (Fig. 2), consistent with dermatofibrosarcoma protuberans (DFSP). Staging showed no evidence of secondary lesions. Given the tumor's size and risk of functional impairment, the patient was started on therapy with imatinib. At the 6-week follow-up, the lesion remained stable.

DFSP is a rare, slow-growing, and locally aggressive soft-tissue tumor[1]. DFSP primarily affects adults, with a peak incidence between 30 and 50 years, and shows a slight male predominance[1,2]. The tumor most commonly occurs on the trunk, followed by proximal extremities and, less frequently, the head and neck[1]. Clinically, it presents as a firm, indurated, nodular, and flesh-colored or violaceous plaque that may initially resemble benign skin lesions, leading to delayed diagnosis[3]. Despite its indolent behavior, DFSP has a high propensity for local recurrence if not completely excised[1,3].

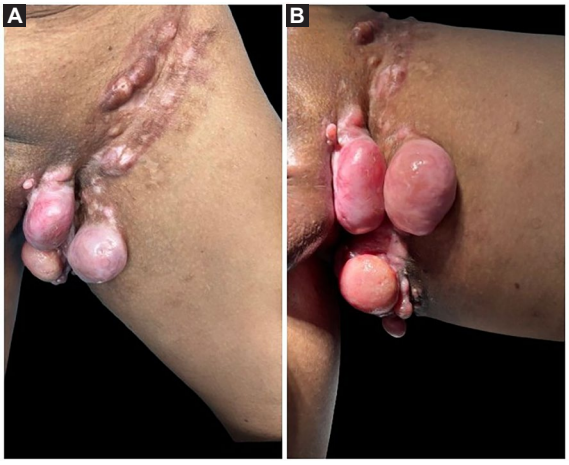

Figure 1. Clinical images with an indurated, flesh-colored plaque with several pedunculated nodules in the left inguinal region (**A:** frontal and **B:** medial views).

Wide local excision with histologically clear margins remains the treatment of choice[4]. Imatinib is an option for patients with unresectable, recurrent, and/or metastatic disease, as well as an alternative to radical surgery in select cases[5]. While metastasis is rare, recurrence poses significant challenges, requiring long-term follow-up[1].

***Correspondence:**
Patrícia Moreira Gomes
E-mail: patriciamgomes0@gmail.com

Received: 27-01-2025
Accepted: 13-02-2025
DOI: 10.24875/PJDV.25000006

Available online: 20-03-2026
Port J Dermatol and Venereol. 2026;84(1):68-69
www.portuguesejournalofdermatology.com

2795-501X / © 2025 Portuguese Society of Dermatology and Venereology. Published by Permanyer. This is an open access article under the CC BY-NC-ND license (http://creativecommons.org/licenses/by-nc-nd/4.0/).

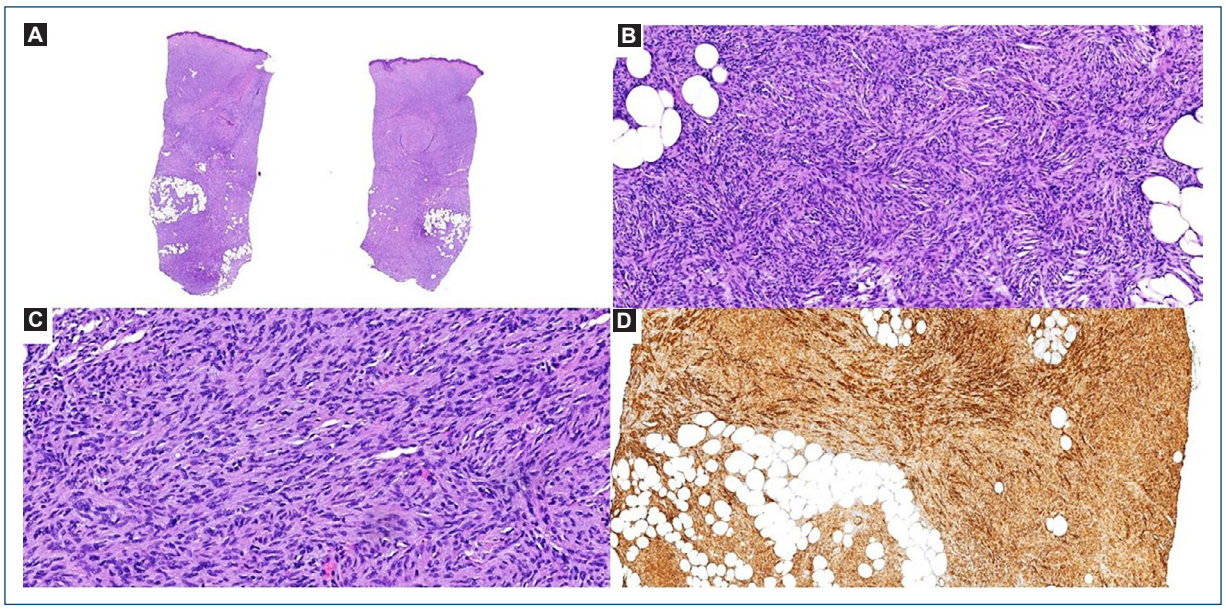

Figure 2. Dermatofibrosarcoma protuberans – low-power magnification with diffuse infiltration of the skin and subcutaneous tissue (**A**: H&E); uniform and medium-sized spindle cells with a storiform or cartwheel pattern of growth (**B**: H&E 100×); minimal atypia and no mitotic figures or necrosis (**C**: H&E 400×); the cells have diffused strong staining for CD34 (**D**: immunohistochemistry 100×).

Funding

None.

Conflicts of interest

None.

Ethical considerations

Protection of humans and animals. The authors declare that no experiments involving humans or animals were conducted for this research.

Confidentiality, informed consent, and ethical approval. The authors have followed their institution's confidentiality protocols, obtained informed consent from patients, and received approval from the Ethics Committee. The SAGER guidelines were followed according to the nature of the study.

Declaration on the use of artificial intelligence (AI). The authors declare that no generative artificial intelligence was used in the writing of this manuscript.

References

1. Jozwik M, Bednarczuk K, Osierda Z. Dermatofibrosarcoma protuberans: an updated review of the literature. Cancers (Basel). 2024;16:3124.
2. Llombart B, Monteagudo C, Sanmartín O, López-Guerrero JA, Serra-Guillén C, Poveda A, et al. Dermatofibrosarcoma protuberans: a clinicopathological, immunohistochemical, genetic (COL1A1-PDGFB), and therapeutic study of low-grade versus high-grade (fibrosarcomatous) tumors. J Am Acad Dermatol. 2011;65:564-75.
3. Bogucki B, Neuhaus I, Hurst EA. Dermatofibrosarcoma protuberans: a review of the literature. Dermatol Surg. 2012;38:537-51.
4. Meng Z, Zhang R, Sun Z, Fu C, Li Z, Wang L, et al. Hotspots and future trends of dermatofibrosarcoma protuberans. Front Oncol. 2024;14:1399486.
5. Navarrete-Dechent C, Mori S, Barker CA, Dickson MA, Nehal KS. Imatinib treatment for locally advanced or metastatic dermatofibrosarcoma protuberans: a systematic review. JAMA Dermatol. 2019;155:361-9.