ANGIOLOGIA E CIRURGIA VASCULAR
PUBLICAÇÃO OFICIAL SPACV

Recanalization of chronic total ilio-caval occlusion

Rita Bento, Ricardo Correia, Maria Emília Ferreira

Department of Angiology and Vascular Surgery, Hospital de Santa Marta, CHULC, Lisbon, Portugal

Submitted: January 16, 2024; **Reviewed:** January 24, 2024; **Accepted:** January 26, 2024.

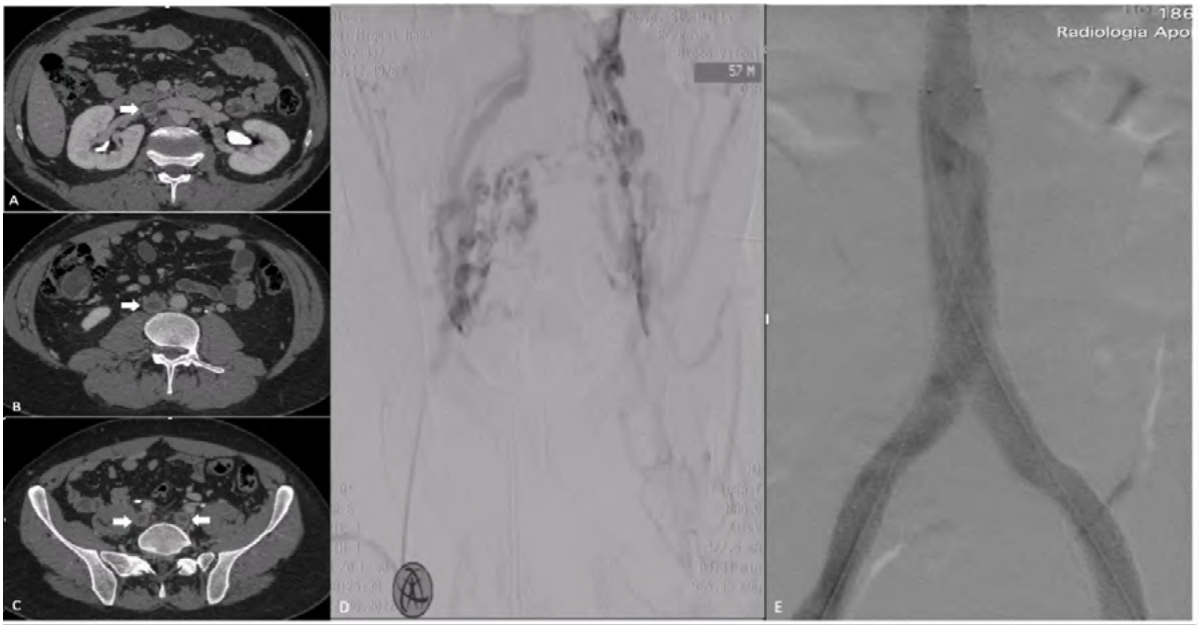

A 45-year-old patient with a previous unprovoked ilio-caval deep venous thrombosis (A,B,C, arrows) and severe post-thrombotic syndrome (long-lasting active venous ulcers, bilaterally) underwent ilio-caval stenting. The initial venography confirmed chronic total occlusion of both iliac veins and the infrarenal inferior vena cava with exuberant pelvic collaterals (D). The iliac occlusions were crossed using an HT Command 0.018 [Abbott®] and standard 0.035 hydrophilic [Terumo®) guidewires and predilated with a 10mm non-compliant balloon. Ilio-caval reconstruction was performed using the confluence technique, with a Sinus XL stent (Optimed®) 20x100mm in the inferior vena cava and Sinus Venous stents (Optimed®) 16x120mm and 14x120mm extending from the iliac vein confluence to the common femoral veins, with an excellent angiographic result (E). Complete venous ulcer healing was observed within two months. Deep venous recanalization has a role in the management of severe post-thrombotic syndrome due to ilio-caval obstruction.

Keywords: Post-thrombotic syndrome, venous ulcers, iliocaval occlusion recanalization

Corresponding Author:
Ana Rita Frade Fialho Bento | ritabento14@hotmail.com
R. de Santa Marta 50, 1169-024 Lisboa

Angiol Vasc Surg 2024;20(3):211
DOI: https://doi.org/10.48750/acv597