ANGIOLOGIA E CIRURGIA VASCULAR
PUBLICAÇÃO OFICIAL SPACV

Conquering complex anatomy: EVAR success in a zig-zagging aortic aneurysm

Tiago Magalhães[a], **Ryan Gouveia e Melo**[a,b,c], **Ruy Fernandes e Fernandes**[a,b,c], **Luís Mendes Pedro**[a,b,c]

[a] Serviço de Cirurgia Vascular, Unidade Local de Saúde Santa Maria, Lisbon, Portugal
[b] Faculdade de Medicina da Universidade de Lisboa (FMUL) Lisbon, Portugal
[c] Centro Cardiovascular da Universidade de Lisboa (CCUL@RISE), Lisbon, Portugal

Submitted: September 9, 2024; **Reviewed:** September 21, 2024;; **Accepted:** October 9, 2024.

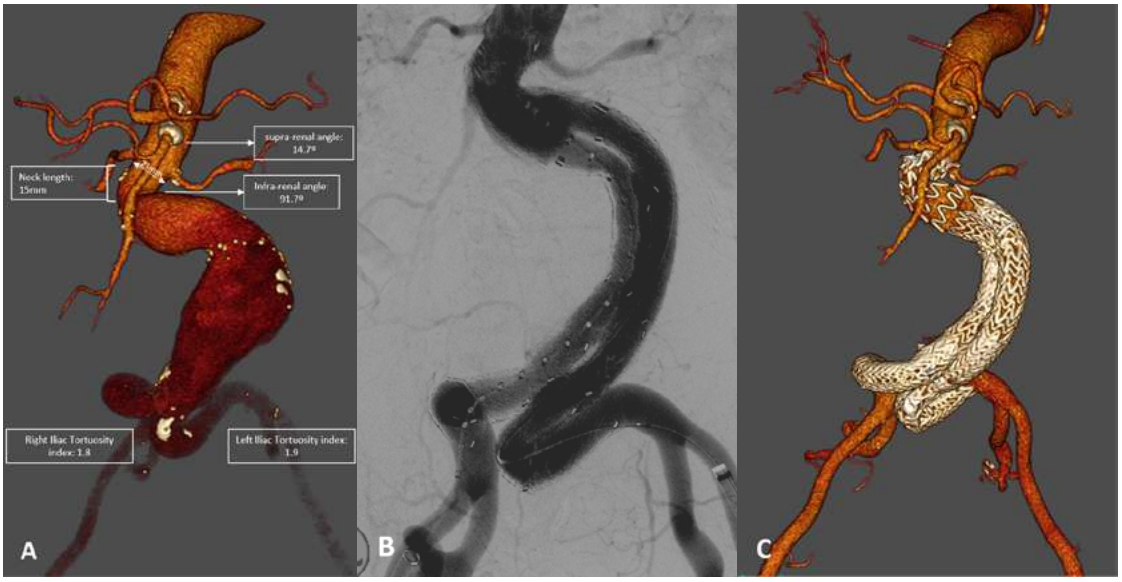

A 92-year-old woman presented to the emergency department with a symptomatic 65cm infra-renal abdominal aortic aneurysm. The computed tomography angiogram showed a severely angulated infra-renal aortic neck and highly tortuous iliac arteries (Panel A), which were out of the instructions for use of standard aortic endografts. Due to her age, open repair was not considered. However, since she was independent and otherwise fit, an EVAR was offered and performed under local anesthesia and through bilateral percutaneous femoral access. Due to the severe angulations, we decided to use the Gore® Excluder® Conformable AAA endoprosthesis. The main body and iliac limbs were advanced over a Terumo® Glidewire Advantage® 0.035'' guidewire and deployed over the floppy 30cm tip to allow for adequate conformability to the different angulations. As shown in Panel B and C, the aneurysm was excluded with perfect conformability to the patient's anatomy, illustrating the advantages of the conformable device.

Acknowledgments: None
Conflicts of interest: None
Funding: None
Data availability: Not applicable
Ethics Approval: Not applicable
Informed Consent: Written Informed consent was obtained from the patient
Declaration of Generative AI and AI-Assisted Technologies in the Writing Process: No generative AI or AI-assisted technologies were used in the writing process.

Corresponding Author:
Tiago Magalhães | tiagomagalhaes99@gmail.com
Hospital de Santa Maria – Unidade Local de Saúde Santa Maria, Serviço de Angiologia e Cirurgia Vascular. Avenida Professor Egas Moniz, 1649-028, Lisboa, Portugal.

Angiol Vasc Surg 2024;20(3):210
DOI: https://doi.org/10.48750/acv640