ANGIOLOGIA E CIRURGIA VASCULAR
PUBLICAÇÃO OFICIAL SPACV

Surgical repair of cervical internal carotid artery aneurysm in a patient with suspected connective tissue disorder

Carlo Campesi, Daniele Mascia, Germano Melissano

San Raffaele Scientific Istitute, "Vita-Salute" University, Faculty of Medicine, Vascular Surgery, Milan, Italy

Submitted: March 16, 2024; **Reviewed:** April 14, 2024; **Accepted:** April 27, 2024

ABSTRACT

BACKGROUND: We present an uncommon case of open surgical treatment of an impacting extra-cranial internal carotid artery aneurysm in a 65-year-old female patient which represented the tip of a large iceberg, in this case, presence of a connective tissue disorder (CTD).

CASE REPORT: Data regarding medical and family history were collected. The patient was referred to our institution due to left latero-cervical mass. Computed tomography angiography showed a large saccular aneurysm of the left internal carotid artery. Open surgical treatment was performed by aneurysmorrhaphy and end-to-end anastomosis. A section of the carotid aneurysmal wall was sent for histological investigation.

The patient was discharged with no neurological issues or cranial nerve injuries. Histological examination of the tissue revealed morphological findings suggestive of a severe degenerative disease.

CONCLUSION: The successful treatment for extracranial carotid artery aneurysm (ECAA) is determined by the carotid artery anatomy and aneurysm properties. The need for early diagnosis and extensive examination in patients with ECAA, as well as clinical suspicion of CTD, plays a crucial role in identifying individuals at risk and guiding optimal management strategies and follow-up.

Keywords: carotid artery; aneurysm; connective tissue disorder

INTRODUCTION

Extra-cranial carotid artery aneurysms (ECAA) are rare and represent a therapeutic challenge for surgeons.[1-3] An ECAA is generally defined as a dilation of the internal carotid artery (ICA) or common carotid artery (CCA) greater than 150% of the diameter of the adjacent healthy artery.[1-3] The true incidence of ECAA is unclear, representing approximately 1% of all carotid artery surgeries.[1] Although atherosclerosis is the most common cause of ICA aneurysms, connective tissue disorders may also predispose to ECAAA or dissection development by altering the vessel-wall structure, with degeneration of the tunica media and elastic lamina. Importantly, because of the high risk of embolic stroke or rupture, with a mortality rate of 70% if left untreated, ECAAA repair is recommended.[3,4]

We report the clinical course, radiological findings, and genetic assessment of a patient with an incidentally discovered ECAA.

CASE REPORT:

A 65-year-old female patient was referred to our center due to a left latero-cervical swelling. She was a non-smoker patient with a history of previous hemithyroidectomy, splenectomy, hysterectomy and adnexectomy, aortic valve, and aortic root replacement due to aneurysmal pathology. She also had a positive family history of aneurysms, with her father having died from a ruptured infrarenal aortic aneurysm (AAA) at the age of 53 and her cousin currently in follow-up for pararenal aneurysm at the age of 44. At presentation, CTD

Corresponding Author:
Carlo Campesi | campesi.carlo@hsr.it
San Raffaele Scientific Institute, "Vita-Salute" University, Faculty of Medicine, Vascular Surgery

Angiol Vasc Surg 2024;20(3):203-6
DOI: https://doi.org/10.48750/acv601

had not been confirmed in either of her family members. No sensory-motor deficits or cranial nerve abnormalities were identified at the neurological examination.

Computed tomography angiography (CTA) showed a saccular aneurysm of the left internal carotid artery with a significant tortuosity (Figures 1 and 2).

Figure 1. Preoperative computed tomography angiography reconstruction of the saccular internal carotid aneurysm



Figure 2. Preoperative computed tomography angiography reconstruction of the saccular internal carotid aneurysm

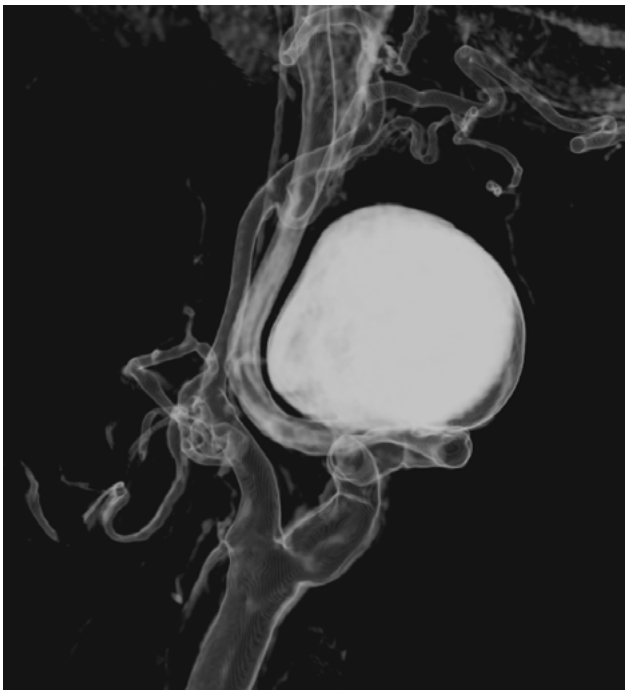

The aneurysm measured 28mm x 30mm and was located near the base of the skull, arising 30mm after the carotid bifurcation. The CTA had also highlighted significant tortuosity of the contralateral ICA but without aneurysmal degeneration. Because of the tortuosity of the ICA, not technically feasible for endovascular repair due to the diameter and absence of optimal distal neck, the volume of the aneurysm, and mass-related symptoms, open repair was preferred to endovascular exclusion as the latter (by excluding the ECAA with a covered stent or embolizing the aneurysm with coil spirals); would not address the mass effect and potential development of permanent cranial nerve injury.

The patient was positioned supine with hyperextension and slight lateral rotation of the neck to the contralateral side; anatomical landmarks were identified and marked. She was intubated with an orotracheal tube and subjected to electroencephalographic monitoring during the procedure. The common carotid artery was isolated to obtain proximal control. The internal and external carotid arteries were also isolated to distal control (Figure 3). Once exposed, the aneurysm was carefully isolated, with gentle traction exerted proximally on the internal carotid artery to displace the caudal, thus improving access for distal (cephalic) control. During clamping, no changes in the EEG registration were identified. The aneurysm was resected, and the internal carotid artery was reconstructed in an end-to-end fashion with interrupted stitches (Prolene 6/0) (Figure 4). No variations to the electroencephalographic pattern were detected following clamp removal. A section of the carotid aneurysmal wall was excised and sent for histological investigation. After three days, the patient was discharged with no neurological issues or cranial nerve injury.

Figure 3. Intra-operative image of the exposed internal carotid artery aneurysm.



Figure 4. Intra-operative image revealing the reconstructed internal carotid artery following aneurysm resection

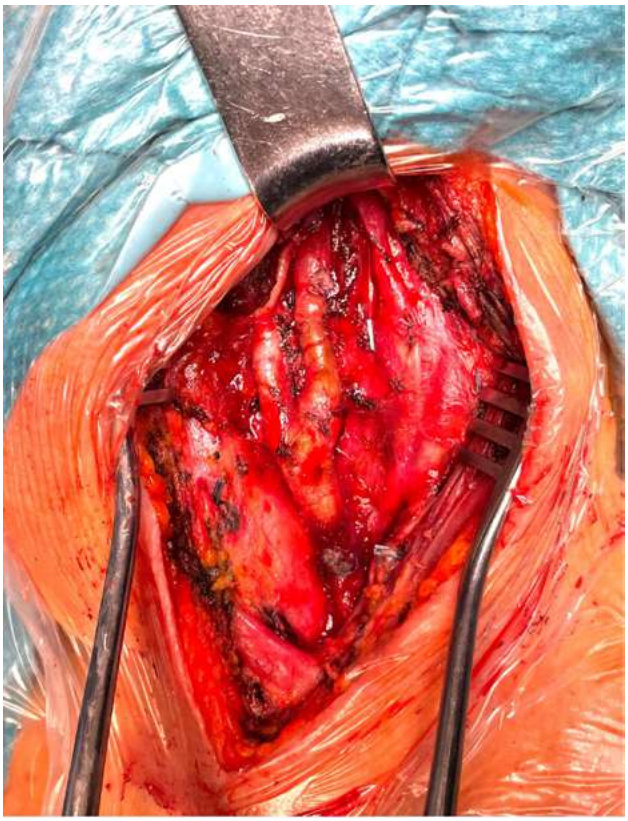

The histological examination showed cellular disorganization of the muscle cells of the tunica media with widespread deposits of mucoid extracellular matrix. The section of the artery also presented discontinuity of the elastic membrane with fragmentation, collapse of the laminae, and marked accumulation of matrix. The morphological findings were suggestive of severe degenerative connective tissue disease.

DISCUSSION

ECAA are rare, accounting for 4% of peripheral aneurysms.[1] Since Sir Astley Cooper's first publication of proximal carotid artery ligation for treating a carotid aneurysm, the etiology, management, and results following aneurysm repair have evolved substantially. Despite the rapid advancement of endovascular techniques, open surgical repair remains the favored approach.[5-6] Treatment is generally recommended for symptomatic or rapidly enlarging ECAA, infection, or when a diameter greater than 20mm is reached.[7-17] The precise mechanisms leading to carotid artery tortuosity and degeneration are unknown. Several studies have suggested histopathologic alterations in tortuous carotid arteries, including degeneration of the tunica medium and elastic lamina, as the basis of the pathological process.[7,12,15,18,19] Patients with tortuous arteries are frequently suspected to have some collagenopathy, but definite diagnosis is often inconclusive.

In turn, CTD has been shown to alter vessel structure and lead to vascular abnormalities such as aneurysms and dissections through various mechanisms, including altered fibrillin-1 structure in Marfan syndrome, collagen mutations in Ehlers-Danlos syndrome (EDS), or transforming growth factor (TGF) signaling pathway abnormalities in Loeys-Dietz syndrome (LDS).[19]

Welby and colleagues described carotid artery tortuosity in 44% of patients with CTD. Tortuosity was frequently bilateral with 30% of all patients with CTD presenting bilateral ICA tortuosity.[12] Among all, patients with Marfan syndrome had the highest prevalence of tortuosity (88%), followed by Loeys-Dietz syndrome (63%), type 1 neurofibromatosis (42%) and other vascular and nonvascular types of CTD (19%).

In particular, histopathologic alterations such as tunica media and elastic lamina degeneration were identified. Additionally, the presence of aortic root dilation or an ascending aortic aneurysm in combination with carotid artery tortuosity was highly associated with CTD with an odds' ratio of 28 and a specificity of nearly 99%.[12-13] These findings suggest that carotid artery tortuosity, particularly when combined with an ascending or root aortic aneurysm or dilatation, is strongly linked to connective tissue disease, as in the case herein reported.[12]

Marfan syndrome is determined by a defect in the structure of fibrillin–1, while LDS arises due to mutations in the TGF-ß protein receptor. Loss of microfibrils consequent to a defect in fibrillin–1 results in aberrant TGF-ß signaling, which is important for the proper formation of the extracellular matrix. Other connective tissue disorders, both vascular and nonvascular, are associated with collagen structure abnormalities rather than elastin.

According to a previous hypothesis, the extracranial ICA may be vulnerable as it represents a transition zone from an elastic to a muscular vessel.[14-15] Given the higher prevalence of carotid tortuosity in patients with Marfan syndrome and LDS, as well as the fact that the mutated proteins in these two disorders are part of the same pathway affecting the biogenesis and maintenance of elastic fibers, it has been hypothesized that changes in elastic fiber structure, rather than collagen structure, are more important contributors to the development of tortuous and aneurysmal vasculature.

In our patient, the histological findings were suggestive of a severe degenerative disease compatible with a connective tissue disorder, which reinforces vascular tortuosity as a significant phenotypic component of CTD individuals.

CONCLUSION

Combination of ascending aortic aneurysm or aortic root dilation with any carotid tortuosity or aneurysm is highly specific for the presence of a CTD. The clinical history of the patient, as well as histopathology, are essential to diagnose and provide adequate management of CTD patients with arteriopathy. Close monitoring following ECAA repair is advised, particularly for individuals with contralateral aneurysms, kinking, or tortuous carotid arteries.

Acknowledgments: None
Conflicts of interest: None
Funding: None
Data availability: Not applicable

Ethics Approval: Not applicable

Informed Consent: Written Informed consent was obtained from the patient

Declaration of Generative AI and AI-Assisted Technologies in the Writing Process: Not applicable

REFERENCES

1. Walter AM, Flett MM, Nagy J, Suttie SA, Dalton A, Casey M, Guthrie GJK. Giant Carotid Artery Aneurysm. Vasc Endovascular Surg. 2021;55:873-7.

2. Ohyama T, Ohara S, Momma F. Aneurysm of the cervical internal carotid artery associated with Marfan's syndrome--case report. Neurol Med Chir (Tokyo). 1992;32:965-8.

3. Garg K, Rockman CB, Lee V, Maldonado TS, Jacobowitz GR, Adelman MA, Mussa FF. Presentation and management of carotid artery aneurysms and pseudoaneurysms. J Vasc Surg. 2012;55:1618-22.

4. Painter TA, Hertzer NR, Beven EG, O'Hara PJ. Extracranial carotid aneurysms: report of six cases and review of the literature. J Vasc Surg 1985;2:312-8.

5. Hertzer NR. Extracranial carotid aneurysms: a new look at an old problem. J Vasc Surg 2000;31:823-5.

6. Beall AC, Jr, Crawford ES, Cooley DA, Debakey ME. Extracranial aneurysms of the carotid artery: report of seven cases. Postgrad Med. 1962;32:93-102.

7. Sfyroeras GS, Nikolopoulou EA, Moulakakis KG, Lazaris AM, Kakisis JD, Geroulakos G. Extracranial Internal Carotid Artery Aneurysm in a Patient with Marfan Syndrome. Ann Vasc Surg. 2019;57:273.e7-10.

8. Hernández JG, Bertomeu AB, Casariego CV, Martínez AB, Hernández-Ávila C, March JR. Acute Nonruptured Expansion of Extracranial Carotid Artery Aneurysm. An Infrequent Clinical Presentation. Ann Vasc Surg. 2021;73:574-84

9. Ben Jmaà H, Lagha A, Diope A, Jarraya F, Bouchech B, Masmoudi S, Boudawara T, Elleuch N, Frikha I. Surgical management of internal carotid artery aneurysm near the skull base. J Med Vasc. 2018;43:262-6.

10. Mascia D, Atique Gabriel S, Kahlberg A, Bertoglio L, Melissano G, Chiesa R. Single-center experience with extracranial carotid aneurysm open repair. J Cardiovasc Surg (Torino). 2020;61:47-52.

11. Qiu J, Zhou W, Zhu X, Zhou W, Zeng Q, Huang L, et al. Treatment of Extracranial Carotid Artery Aneurysm: Fifteen Years' Experience at a Single Institution. Ann Vasc Surg. 2020;69:174-81.

12. Welby JP, Kim ST, Carr CM, Lehman VT, Rydberg CH, Wald JT, et al.. Carotid Artery Tortuosity Is Associated with Connective Tissue Diseases. AJNR Am J Neuroradiol. 2019;40:1738-43.

13. Welleweerd JC, den Ruijter HM, Nelissen BG, Bots ML, Kappelle LJ, Rinkel GJ, et al. Management of extracranial carotid artery aneurysm. Eur J Vasc Endovasc Surg. 2015;50:141-7.

14. Attigah N, Külkens S, Zausig N, Hansmann J, Ringleb P, Hakimi M, et al. Surgical therapy of extracranial carotid artery aneurysms: long-term results over a 24-year period. Eur J Vasc Endovasc Surg. 2009;37:127-33.

15. Li Z, Chang G, Yao C, Guo L, Liu Y, Wang M, Liu D, et al. Endovascular stenting of extracranial carotid artery aneurysm: a systematic review. Eur J Vasc Endovasc Surg. 2011;42:419-26.

16. Garg K, Rockman CB, Lee V, Maldonado TS, Jacobowitz GR, Adelman MA, et al. Presentation and management of carotid artery aneurysms and pseudoaneurysms. J Vasc Surg. 2012;55:1618-22.

17. Painter TA, Hertzer NR, Beven EG, O'Hara PJ. Extracranial carotid aneurysms: report of six cases and review of the literature. J Vasc Surg. 1985;2:312-8

18. Han HC. Twisted blood vessels: symptoms, etiology and biomechanical mechanisms. J Vasc Res. 2012;49:185-97.

19. Kim ST, Brinjikji W, Lanzino G, Kallmes DF. Neurovascular manifestations of connective-tissue diseases: A review. Interv Neuroradiol. 2016;22:624-37.