

CASE REPORT

Cutaneous Plasmacytosis: Diagnostic and Therapeutic Challenge in a Patient with an Atypical Presentation

Plasmocitose Cutânea: Desafio Diagnóstico e Terapêutico num Doente com Apresentação Atípica

Received/Recebido
2021/02/26Accepted/Aceite
2021/05/11Published/Publicado
2021/09/30Gustavo Moreira Amorim^{1,2*}, Ariel Córdova Rosa³, Joana Buratto^{1,4}, Solange Emanuelle Volpato Steckert², Roberto Moreira Amorim Filho², Gabriella Di Giunta Funchal³¹Faculty of Medicine - Universidade do Sul de Santa Catarina - UNISUL/Pedra Branca, Santa Catarina, Brazil²Sector of Dermatology - Hospital de Dermatologia Sanitária Santa Teresa - Secretaria do Estado de Saúde de Santa Catarina, Santa Catarina, Brazil³Sector of Dermatology and Pathology - Hospital Universitário Polydoro Ernani de São Thiago - Universidade Federal de Santa Catarina - HU/UFSC, Santa Catarina, Brazil⁴Primary Care - Secretaria Municipal de Saúde de São José.

ABSTRACT – Cutaneous plasmacytosis is a rare dermatosis that is classically characterized by the presence of multiple papules and reddish-brown nodules mainly in the trunk. It most commonly affects elderly Asians, with few reports in Caucasians and young patients. On histopathology there is a polyclonal proliferation of mature plasma cells.

The objective of this report is to present a case of atypical manifestation of this rare disease, both due to clinical and epidemiological aspects.

KEYWORDS – Plasma Cells; Skin Diseases.

RESUMO – A plasmocitose cutânea é uma dermatose rara que em sua forma clássica se caracteriza pela presença de múltiplas pápulas e nódulos castanho-avermelhados principalmente no tronco. Acomete mais frequentemente asiáticos idosos, com poucos relatos em caucasianos e em pacientes jovens. Na histopatologia observa-se proliferação policlonal de plasmócitos maduros. O objetivo deste relato é apresentar um caso de manifestação atípica desta rara doença, tanto pelos aspectos clínicos quanto epidemiológicos.

PALAVRAS-CHAVE – Doenças da Pele; Plasmócitos.

INTRODUCTION

Cutaneous plasmacytosis is a rare dermatosis that in its classical form is characterized by the presence of multiple reddish-brown papules and nodules, mainly on the trunk. It most often affects elderly Asians,¹ with few reports in Caucasians and young individuals.^{2,3} Cutaneous histopathology shows dermal polyclonal proliferation of mature plasma cells, without atypia. Definitive diagnosis tends to be delayed.¹

The purpose of this report is to present a case with atypical manifestation of this rare disease, both for clinical and epidemiological aspects.

CASE REPORT

A 21 years-old male patient referred an asymptomatic patch on his right thigh, that began when he was 12 years old, slowly enlarged with a downward progression to the leg and new similar lesions on the contralateral lower limb (Figs 1 and 2). On examination, erythematous-purple well demarcated patches on the legs with a geographical pattern or a more reticular pattern on the thighs were partially reducible with diascopy (Fig. 3). Lesions showed no skin indurating and distribution of body hair and sensitivity was preserved. He denied fever and other systemic symptoms. There were no palpable lymph nodes, hepato- or splenomegaly on physical examination.

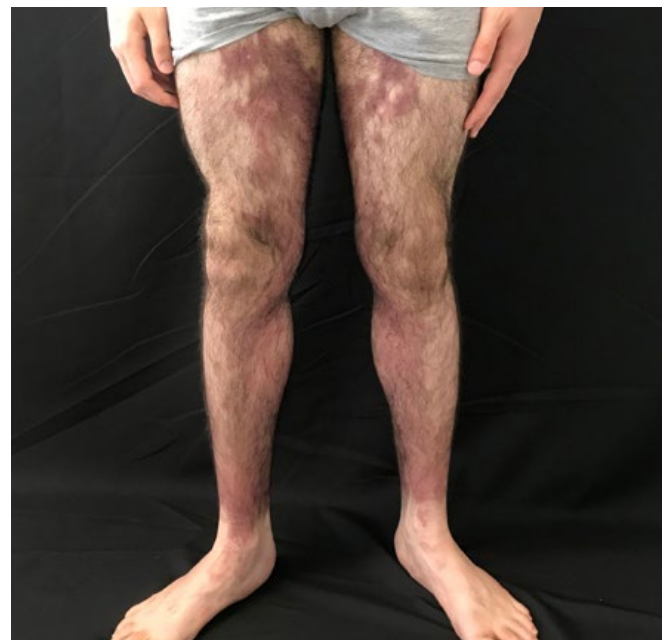

Figure 1 - Anterior view of lower limbs: red-brown macules mainly in the medial portion of the thighs and legs, with well-defined limits and a geographical pattern.

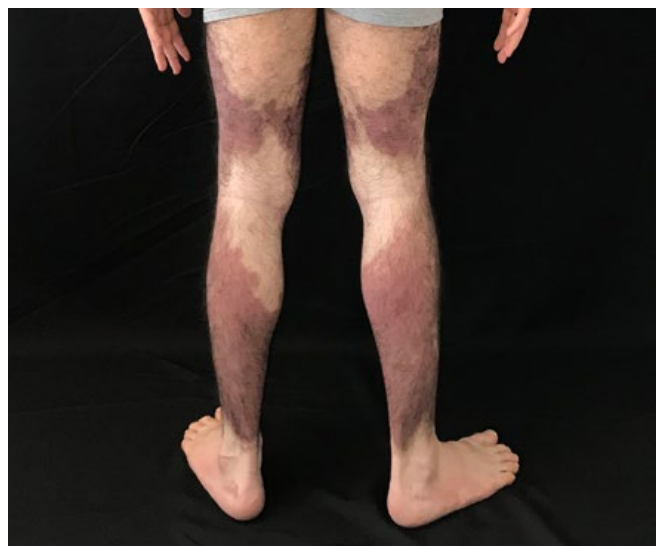


Figure 2 - Posterior view of lower limbs: red-brown macules, bilaterally, with a descending linear aspect, with marked symmetry.

Blood cell count and serum biochemistry was normal. Serum protein electrophoresis demonstrated 6.8 g/L of total proteins, with an albumin of 4.37 g/L and an albumin/globulin ratio of 1.80, without a monoclonal peak. Bence-Jones protein urine was negative as well

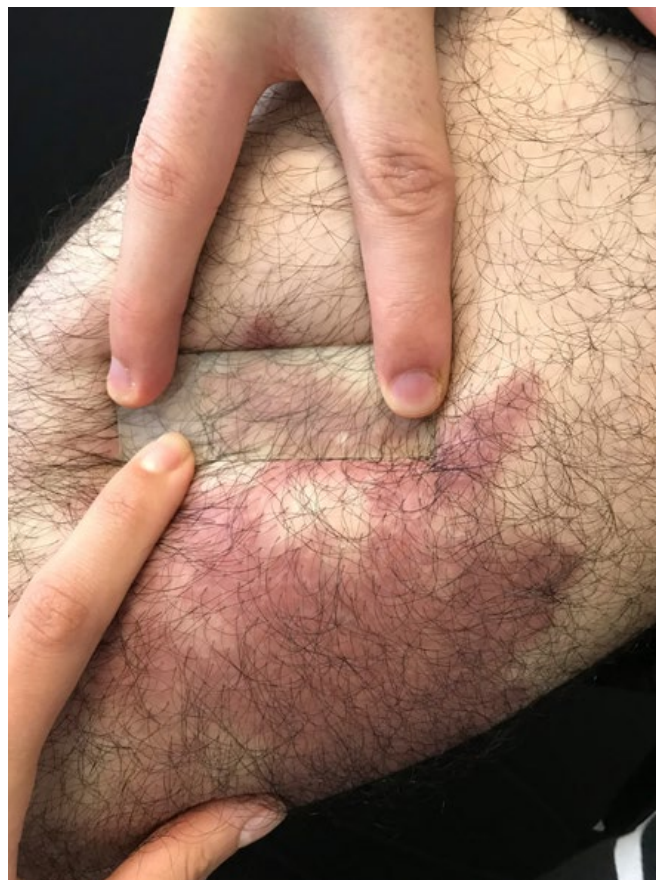

Figure 3 - Detail of erythematous-purple patches, partially reducible with diascopy.

as syphilis and borreliosis serology. Three cutaneous histopathology exams performed on the thighs with 6 years interval, all exhibited the same pattern, however, with a progressive increase in the intensity and representativeness of the findings. In the dermis, throughout the whole thickness of the sample, we observed epithelioid granulomas and perivascular and peri-adnexal cuffs made up of numerous plasma cells, histiocytes and lymphocytes extending to the interstitial dermis and permeating collagen bundles. Plasma cells were slightly enlarged but without atypia. Central nervous system magnetic resonance imaging and chest, abdomen and pelvis computed tomography scan were normal. No bone marrow investigation was recommended by the Hematologist who evaluated the patient.

There was no improvement with oral colchicine (1 g/day, p.o., for 6 months), doxycycline (200 mg/day, p.o., for 6 weeks) and systemic corticosteroids (prednisolone 1 mg/kg/day during 1 month, with slow dosage tapering and complete withdrawal after 2 months) associated either with mometasone 0.1% cream or clobetasol propionate cream.

After reviewing the last cutaneous histopathology we could characterize a dense superficial and deep perivascular and periadnexal infiltrate composed by numerous plasma cells, histiocytes and lymphocytes permeating collagen bundles with a “rosette” aspect, along with hemosiderin deposits (Fig. 4). Infiltrating cutaneous plasma cells were polyclonal exhibiting both κ - and λ -chains in immunohistochemistry (Fig. 5). Those findings, in correlation with the clinical aspects, suggest the diagnostic hypothesis of cutaneous plasmacytosis.

Approximately 12 months after this presumptive diagnosis there was no apparent worsening and still no signs of systemic involvement, therefore a new treatment protocol using thalidomide with phototherapy was initiated, still with almost no improvement after 20 sessions of narrow-band UVB (NB-UVB).

DISCUSSION

In 1976, Yashiro *et al* first describe a case of a patient with cutaneous lesions where the biopsy showed a dense perivascular infiltrate of mature plasma cells, without a detectable underlying disease, suggesting that it could be “a kind of plasmacytosis”.⁴

In the 80’s, other reports with similar cutaneous and histopathological findings were reported but sometimes associated with lymphadenopathy and polyclonal hypergammaglobulinemia.⁵⁻⁷ Among them, Aso *et al*, in 1982, reported a case exclusively with skin lesions, without any other symptoms or findings, and classified the disease with the term “cutaneous plasmacytosis”.⁶

Cutaneous plasmacytosis is considered to be a rare skin disease determined by benign cutaneous proliferation of mature plasma cells. Exact etiology and pathogenesis are still unknown. Plasma cell dysfunction appears to be associated with increased interleukin 6, a cytokine with a relevant role in the differentiation of B cells to plasma cells. Infection by human herpesvirus 8 may be also implicated, but was not assessed in this patient.^{8,9}

Taking into account the possibility of systemic symptoms, some authors prefer the term “cutaneous and systemic plasmacytosis” to account for the extracutaneous involvement. However, as defined, there should be no significant underlying disease.^{10,11} Particularly in this case, systemic involvement has been ruled out after a long follow-up and extensive and repeated clinical, laboratory and image exams. Therefore, we tend to consider it as a cutaneous isolated form, at least by now, but follow-up will be repeated at annual intervals.

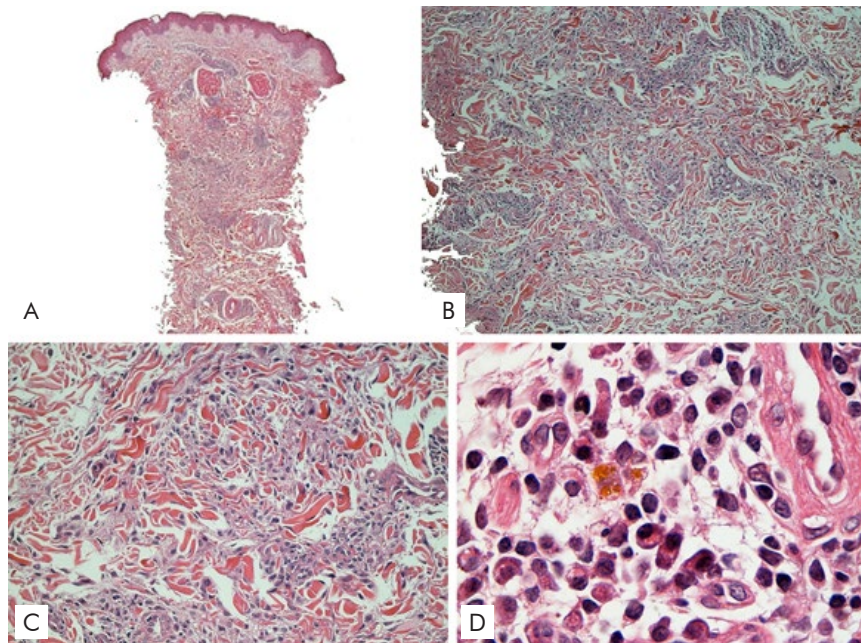


Figure 4 - Assembly of 4 photomicrography images, in H&E stain, showing, in 4A, 4B and 4C, Interstitial Granulomatous Dermatitis pattern. 4D, in a 100x objective, detailing the massive presence of plasma cells in the infiltrate.

Clinically, cutaneous plasmacytosis lesions are asymptomatic and progressive with multiple reddish-brown infiltrated macules, plaques and nodules, mostly on the trunk. The disease affects more often the elderly and Asians, unlike the case presented where the patient was a Caucasian with the lesional onset during childhood. In addition, the main site of reported involvement is the trunk, with progression to the

histopathological differential diagnosis, however clinically there was no sclerosis or atrophy. Infectious diseases, such as syphilis and borreliosis, could exhibit similar histopathological findings, however, serologies were non-reactive, in several occasions. Finally, the polyclonality of the infiltrate excludes a malignant neoplastic process.

There is no standardized treatment for this disease, and most of

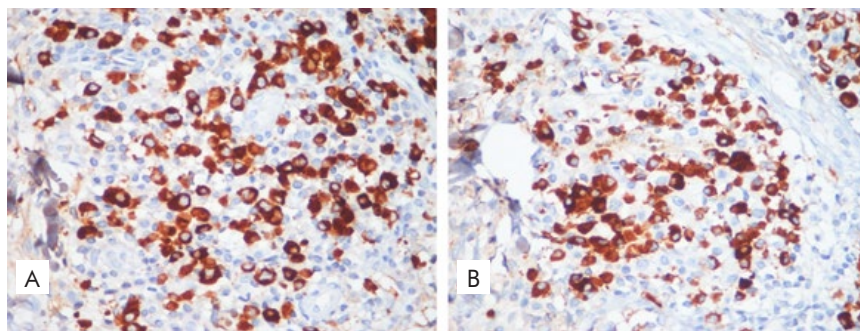


Figure 5 - Polyclonality of infiltrating plasma cells of both κ - and λ -chain-positive cells was demonstrated with immunohistochemistry (400x).

upper limbs in those with disease for more than 2 years, which also differs from the case in which the lower limbs were the main areas affected. Axillary involvement is also reported in patients with long-standing skin disease, which was not observed in this patient.⁸

Clinical manifestations may include fever, anemia, lymphadenopathy and hypergammaglobulinaemia.¹² The patient in the present case had none of these manifestations.

Histopathology is characterized by the presence of moderately deep and superficial perivascular infiltrate of plasma cells without atypia. Immunohistochemistry shows polyclonal plasma cells with positivity for both κ and λ chains in similar proportions, with perineural distribution described in most cases.^{8,13} Scleroderma is a relevant

the information was obtained from isolated case reports and small case series. Topical treatments include corticosteroids and calcineurin inhibitors. Systemic corticosteroids, thalidomide (probably associated with reduced IL6 secretion), ultraviolet-A (UVA) and narrow-band ultraviolet-B (NB-UVB) phototherapy (related to elevation of IL-10 with consequent IL6 suppression) are other options.^{8,14} A good response was reported with 308-nm excimer lamp, with a mechanism supposedly similar to NB-UVB.¹⁵ The present patient has not responded to topical or systemic corticosteroid therapy neither to NB-UVB and thalidomide.

Despite the difficulty to achieve complete clearance with the available treatment options, the prognosis of the majority of patients with cutaneous/systemic plasmacytosis is favorable.⁸

CONCLUSION

With this illustrative case we aim to draw attention to this rare entity, discussing the relevant literature to the topic. We emphasize the importance of bringing clinical dermatology closer to pathology. Clinico-histopathological correlation was fundamental for the adequate diagnosis of this patient. This seems to be the first Brazilian report of Cutaneous Plasmacytosis recorded in the literature.

Conflicts of Interest: The authors have no conflicts of interest to declare. **Financing Support:** This work has not received any contribution, grant or scholarship. **Confidentiality of Data:** The authors declare that they have followed the protocols of their work center on the publication of data from patients. **Patient Consent:** Consent for publication was obtained. **Provenance and Peer Review:** Not commissioned; externally peer reviewed.

Conflitos de Interesse: Os autores declaram a inexistência de conflitos de interesse na realização do presente trabalho. **Fontes de Financiamento:** Não existiram fontes externas de financiamento para a realização deste artigo. **Confidencialidade dos Dados:** Os autores declaram ter seguido os protocolos da sua instituição acerca da publicação dos dados de doentes. **Consentimento do doente para publicação obtido.** **Proveniência e Revisão por Pares:** Não comissionado; revisão externa por pares.

ORCID

Gustavo Moreira Amorim: <https://orcid.org/0000-0001-6067-9463>
Ariel Córdova Rosa: <https://orcid.org/0000-0003-4040-2891>
Joana Buratto: <https://orcid.org/0000-0001-7945-538X>
Solange E. Volpato Steckert: <https://orcid.org/0000-0002-8450-5959>
Roberto M. Amorim Filho: <https://orcid.org/0000-0002-1897-4079>
Gabriella Di Giunta Funchal: <https://orcid.org/0000-0001-8383-2918>

Corresponding Author: Gustavo Moreira Amorim

Address: 135 Duarte Schutel street. Apartment 402, Downtown, Florianópolis, Santa Catarina, Brazil. CEP: 88015-640
E-mail: gustavomoreiraamorim@hotmail.com

© Author(s) (or their employer(s)) 2021 SPDV Journal. Re-use permitted under CC BY-NC. No commercial re-use.

© Autor (es) (ou seu (s) empregador (es)) 2021 Revista SPDV. Reutilização permitida de acordo com CC BY-NC. Nenhuma reutilização comercial.

REFERENCES

1. Wagner G, Rose C, Klapper W, Sachse MM. Cutaneous and systemic plasmacytosis. *J Dtsch Dermatol Ges.* 2013; 11: 1161-7. doi: 10.1111/ddg.12190.
2. Gilliam AC, Mullen RH, Oviedo G, Bhatnagar R, Smith MK, Patton DF, et al. Isolated benign primary cutaneous plasmacytosis in children: Two illustrative cases. *Arch Dermatol.* 2009; 145: 299-302.
3. González-López MA, González-Vela MC, Blanco R, Fernández-Llaca H, Val-Bernal JF. Cutaneous plasmacytosis limited to the extremities in a white patient: An unusual clinical picture. *Cutis.* 2010; 86: 143-7.
4. Uhara H, Saida T, Ikegawa S, Yamazaki Y, Mikoshiba H, Nijoh S, et al. Primary cutaneous plasmacytosis: report of three cases and review of the literature. *Dermatology.* 1994; 189: 251-5.
5. Kitamura K, Tamura N, Hatano H, Toyama K, Mikata A, Watanabe S. A case of plasmacytosis with multiple peculiar eruptions. *J Dermatol.* 1980; 7: 341-9.
6. Aso M, Shimao S. An unusual case of cutaneous plasmacytosis. *J Dermatol.* 1982; 9: 149-52.
7. Watanabe S, Ohara K, Kukita A, Mori S. Systemic plasmacytosis. *Arch Dermatol* 1986; 122: 1314-20.
8. Hsiao PF, Wu YH. Characterization of cutaneous plasmacytosis at different disease stages. *Dermatology.* 2016; 232: 738-47. doi: 10.1159/000456073.
9. Jayaraman AG, Cesca C, Kohler S. Cutaneous plasmacytosis: A report of five cases with immunohistochemical evaluation for HHV-8 expression. *Am J Dermatopathol.* 2006; 28: 93-8.
10. Tada Y, Komine M, Suzuki S, Kikuchi K, Sasaki M, Kaneko N, et al. Plasmacytosis: Systemic or cutaneous, are they distinct? *Acta Derm Venereol.* 2000; 80: 233-5.
11. Honda R, Cerroni L, Tanikawa A, Ebihara T, Amagai M, Ishiko A. Cutaneous plasmacytosis: Report of 6 cases with or without systemic involvement. *J Am Acad Dermatol.* 2013; 68: 978-85. doi: 10.1016/j.jaad.2012.11.031.
12. Cutaneous plasmacytosis: A rare entity with unique presentation. *Indian J Dermatol Venereol Leprol.* 2017; 83: 673-6.
13. Han XD, Lee SJ, Tan SH, Chong WS, Ng SK, Ooi MG, et al. Cutaneous plasmacytosis: A clinicopathologic study of a series of cases and their treatment outcomes. *Am J Dermatopathol.* 2018; 40: 36-42. doi: 10.1097/DAD.0000000000000907.
14. Omura R, Sowa-Osako J, Fukai K, Kusutani N, Takeoka Y, Koh H, et al. Promising therapeutic option for cutaneous plasmacytosis: 308-nm excimer lamp. *J Dermatol.* 2018; 45: e215-6. doi: 10.1111/1346-8138.14262.
15. Yanaba K, Kajii T, Matsuzaki H, Umezawa Y, Nakagawa H. Cutaneous plasmacytosis successfully treated with narrowband ultraviolet B irradiation therapy. *J Dermatol.* 2016; 43: 229-30. doi: 10.1111/1346-8138.13164.