Artigo de Revisão
Review Article

Antonio Murinello*[1]
A Manuel Figeiredo*[2]
Júlio Semedo**[3]
Helena Damásio*[4]
N Carrilho Ribeiro***[5]
Helena Peres****[6]

Empiema torácico – Revisão baseada em três casos clínicos

Thoracic empyema – A review based on three cases reports

Recebido para publicação/*received for publication:* 08.10.27
Aceite para publicação/*accepted for publication:* 08.12.16

Resumo

O derrame parapneumónico caracteriza-se pela necessidade de um processo invasivo para a sua resolução e o empiema pela presença de pus na cavidade pleural. Em ambos os casos, o diagnóstico por TAC e o tratamento precoces resultando em menores morbilidade e mortalidade. São indicação para um tratamento invasivo os derrames loculados, os que ocupam mais de 50% do tórax, os que revelam coloração por Gram e exame cultural positivos, ou derrames com pH inferior a 7,20, glucose inferior a 60 mg/dl, e nível de DHL superior a três vezes o limite normal no soro. Estas características resultam da evolução

Abstract

Complicated parapneumonic effusion is one in which an invasive procedure is necessary for its resolution and empyema means pus in the pleural space. An early diagnosis and therapy of these conditions results in less morbidity and mortality. CT of the chest is important to study complex pleural effusions. Loculated effusions, those occupying more than 50% of the thorax, or which show positive Gram stain or bacterial culture, or a purulent effusion with a pH below 7.20, with a glucose level below 60 mg/dl or a LDH level more than three times the upper limit of normal for serum, are indications for an invasive pro-

[1] Chefe de Serviço Graduado de Medicina Interna/*Unit Head, Internal Medicine graduate*
[2] Interno de Especialidade de Medicina Interna/*Intern, Internal Medicine*
[3] Assistente Hospitalar Graduado de Pneumologia/*Consultant, Pulmonology graduate*
[4] Assistente Hospitalar Graduada de Medicina Interna/*Consultant, Internal Medicine graduate*
[5] Director de Serviço de Radiologia/*Director, Radiology Unit*
[6] Assistente Hospitalar Graduada de Patologia Clínica/*Unit Consultant, Clinical Pathology graduate*

Institutions and units:
* Hospital Curry Cabral – Internal Medicine
** Hospital Pulido Valente – Pneumology
*** Hospital Curry Cabral – Radiology
**** Hospital Curry Cabral – Pathology

através de três estádios dos derrames incorrectamente tratados: 1) exsudativo; 2) fibrino-purulento; 3) fibrótico. Dependendo do estádio evolutivo, a abordagem terapêutica varia entra toracentese terapêutica, colocação de drenagem torácica com ou sem instilação de fibrinolíticos, cirurgia toracoscópica vídeo-assistida e decorticação pulmonar. Os autores fazem uma revisão do estudo destas situações baseados em três casos clínicos com apresentações muito díspares: uma doente com empiema por *Streptococcus pyogenes* que faleceu rapidamente por hemoptise maciça; um doente com empiema resultante de pneumonia aguda ocorrida durante um voo de avião; uma doente com empiema e bacteriemia por *Streptococcus pneumoniae* conduzindo a diagnóstico até então desconhecido de infecção por VIH.

Rev Port Pneumol 2009; XV (3): 507-519

Palavras-chave: Empiema, derrame parapneumónico, *Streptococcus pyogenes,* pneumococos, VIH, avião.

cedure. These characteristics result from the evolution of a not well treated parapneumonic effusion, through the three stages: (1) exsudative; (2) fibrinopurulent; (3) fibrotic. Depending on the stage therapeutic methods vary from therapeutic thoracentesis, insertion of a chest tube with or without instillation of fibrinolytics, video-assisted thoracoscopic surgery, and lung decortication. A review of all these aspects are done based on a series of three cases reports with very different clinical presentation: one patient with empyema by *Streptococcus* pyogenes and that died rapidly due to massive hemoptysis; a patient with empyema due to acute pneumonia developing during an airflight; a patient with empyema and bacteraemia by *Streptococcus pneumonia* leading to the diagnosis of an unknown HIV infection.

Rev Port Pneumol 2009; XV (3): 507-519

Key-words: Empyema, parapneumonic effusion, *Streptococcus pyogenes*, pneumococcus, HIV.

Introduction

Parapneumonic effusion occurs in 20-40% of patients who are hospitalized with pneumonia, the majority of which follow an uncomplicated course responding to isolated therapy with antibiotics[1]. However some pleural effusions have a complicated course, which means that an invasive process is considered necessary for its resolution, or that its bacterial cultures are positive. Pus in the pleural space is named empyema. Delays in diagnosis and treatment of these complicated effusions results in increased morbidity, detrimental effect of unresolved sepsis and compromised respiratory function on quality of life, including loss of livelihood[2]. These considerations emphasizes the need for early and if necessary serial chest radiographies to prevent delay in the diagnosis of complicated pleural effusions. CT of the chest is the imaging study of choice for complex fluid collections. Pleural contrast enhancement and increased attenuation of extrapleural subcostal fat have been associated with pleural infection, and absence of pleural thickening on CT is more suggestive of non-complicated parapneumonic effusion than empyema[3].

Characteristics of effusions that indicate an invasive procedure will be necessary for its resolution are: an effusion occupying more than 50% of the hemithorax or one that is loculated; a positive Gram stain or culture of the pleural fluid; and a purulent effusion that has a pH below 7.20 or a glucose level below 60 mg/dl, or a LDH level of more than three times the upper normal limit for serum[4,5].
Considering the therapeutic decisions about these effusions several points of management shall be considered. If the pleural fluid cannot be removed with a therapeutic thoracentesis, a chest tube should be inserted and consideration be given to the intrapleural instillation of fibrinolytics. If the loculated effusion persists, the patient should be subjected to video-assisted thoracoscopic surgery[6,7], and if the lung cannot be expanded with this procedure, a full thoracotomy with decortication should be performed[8,9]. The definitive procedure should be performed within 14 days[5].

Case 1

A 55-year-old white woman was admitted to our Unit on the night of 07 FEB 05, after a prior evaluation on the Emergency ward of our Hospital. She referred chronic depression and hypertension, denying any other previous disease and also smoking, alcoholic and drug addiction, and no risky sexual behavior. She began to feel sick one week earlier, complaining of slight fever, myalgias, odinalgia and hoarseness. Two days before admission she complained of right pleuritic pain, cough with hemoptoic sputum, and increasing dyspnoea on rest. She was oriented, had a temperature of 36.9º C, blood pressure was 164/83 mmHg, heart rate 106 bpm, and had a superficial respiratory rate of 24 p/mn. She was slightly icteric, there was labial herpetic lesions and erythema of the oropharynx. Thoracic semiology was in favour of voluminous right pleural effusion, and there was slight hepatomegaly. Blood LAB tests on the Emergency Ward revealed: no anemia nor thrombocytopenia, leucocytes 5.700/mm^3 with 93.6% of neutrophils and 216/mm^3 of lymphocytes; PCR > 9 mg/dl (<1.0); arterial gasometry – pH 7.480, pO_2 58.3 mmHg, pCO_2 27.3 mmHg, $HCO3^-$ 20.1 mmol/L, O_2 sat. 41.9%; cardiac enzymology was normal; blood biochemistry: urea 49.8 mg/dl; creatinine 1.1 mg/dl; glucose 166 mg/dl; normal ionogram, LDH 832 UI/L (313-618). Electrocardiogram was normal. A voluminous right pleural effusion was demonstrated on the x-Ray of the thorax (Fig 1A). Thoracentesis was realized with drainage of 750 ml of empyema (Fig 1B). A pleural catheter for continuous drainage was not inserted. LAB examination of the empyema showed: glucose < 10 mg/dl, protein 5.3 g/dl, many granulocytes and a myriad of Gram positive *coccus* that on culture were revealed as *Streptococcus pyogenes* (Fig 2) sensible to penicillin. Empiric therapy were already been initiated with e.v. ceftriaxone and gentamicin, together with e.v. hydrocortisone. At our Unit, 10 hours after previous drainage on the Emergency Ward, the clinical picture was seriously worse, the patient had accentuated polypnoea and had orthopnoea, peripheral cianosis, and tachycardia. The x-Ray of the thorax showed fast re-accumulation and worsening of pleural fluid effusion (Fig. 1C). She was immediately transferred to the Pneumology Unit of the Hospital Stª Marta, where she died 2

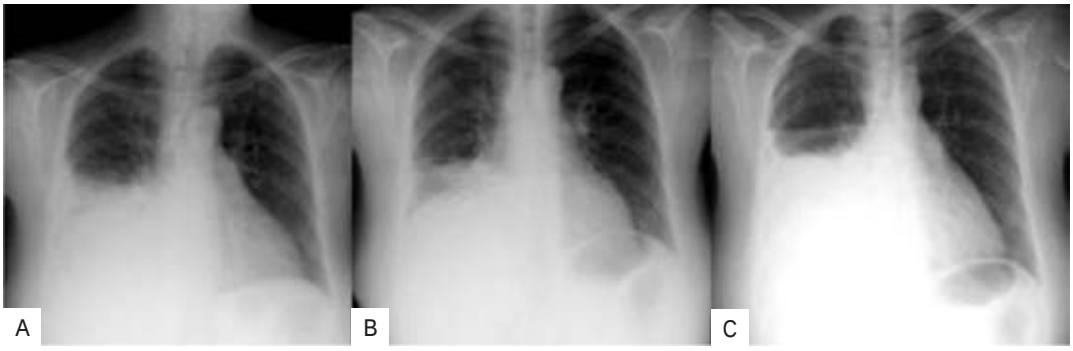

Fig. 1 – A – PA view of thorax X-ray at admission; B – PA view of thorax X-ray after drainage of 750 ml of pus; C – PA view of thorax X-ray – 10 hours after previous drainage of pus

hours later due to massive haemoptysis. Necropsy was not authorized by his family. Several days later the Pathology Department detected a co-existent positive culture of pleural effusion with a non-identified atypical *Mycobacteria.* The HIV status of the patient was unknown.

Comment

Invasive group A *Streptococcus* infections occur rarely but are serious, and can manifest as streptococcal toxic shock syndrome, soft-tissue infections (fasciitis, myositis, cellulitis, erysipelas), bacteraemia, pneumonia, peritonsilar or retropharyngeal abscess, sinusitis. In addition to suppurative complications, nonsuppurative complications can also occur, as acute rheumatic fever, post-streptococcal glomerulonephritis, central nervous system diseases[10]. The main virulence factor of the group A *streptococcus* is the cell wall M-protein that inhibits complement activation and decreases phagocytosis[11].

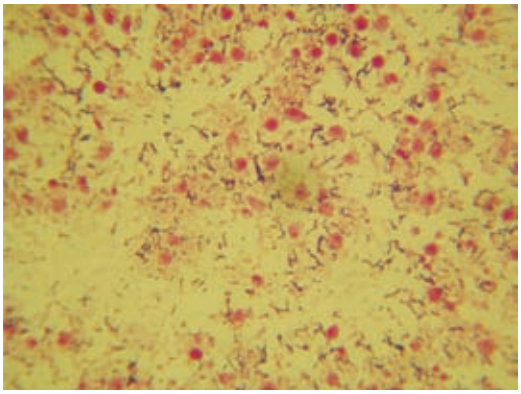

Fig. 2 – Gram stain: innumerous Gram + coccus in the pus, identified by culture as *Streptococcus pyogenes*

Streptococcus pyogenes is an uncommon cause of community-acquired pneumonia (CAP) that sometimes occurs as a secondary infection following acute viral infections (measles, influenza, varicella) or bacterial infections as by *H. pertussis* in COPD patients, or after streptococcal pharyngitis. Entry of the microorganism into the lung usually results from inhalation or microaspiration. Rarely, streptococcal pneumonia is due to hematogenous seeding from other infected sites[11]. In the pre-antibiotic era epidemic streptococcal pneumonia was more frequent, occurring in institutions where close contact predisposed to transmissibility, as for example in military recruit populations[12] or in nursing homes. Most recent series report a high frequency of association of sig-

nificant chronic illness (chronic lung disease, cardiac disease, cancer, alcohol abuse, diabetes mellitus, intravenous drug use, renal impairment, cirrhosis, HIV infection, systemic lupus erythematosus, organ transplant recipients)[13].

The presenting clinical features of *Streptococcus pyogenes* pneumonia are usually high fever, chills, sore throat, cough and frequently purulent sputum, pleuritic pain, rapid onset of dyspnoea, and sometimes hemoptysis. Myalgias, confusion, meningeal signs and a widespread rash ("purpura fulminans") may occur[14]. The most typical feature suggesting this diagnosis, however, is the rapid accumulation of a pleural empyema ("explosive pleuritis") in a patient presenting with acute respiratory infection (80% of the cases), and that rapidly progress to loculated empyema. Pleural empyemas due to group A *beta-hemolytic streptococci* is uncommon in the antibiotic era, although more frequent in children and neonate[15,16]. In adults it has not been widely reported except for some reviews and case reports[11,17]. *Streptococcus pyogenes* has singled out as the case of small pneumonia with extensive empyema[18].

Other complications of *Streptococcus pyogenes* pneumonia are necrotizing pneumonia leading to lung abscess and extending infection, pneumatocele, pneumothorax, bronchopleural fistula and more uncommonly pericarditis, osteomyelitis, metastatic abscesses, septicaemia and shock[17]. A rare and serious complication is hypertensive pyopneumothorax[19].

These pneumonias have potentially high mortality and have a slow response to antibiotic therapy. Even with urgent drainage of empyemas by chest tube the evolution is many times dismal, with a case fatality rate of 30 to 60% of the cases depending on the series, occurring more commonly in patients with bacteraemia. The progression of fatal cases is generally rapid, with a median time to death of 2 days, even in the absence of underlying medical conditions[14].

Hemoptysis is a significant and frightening clinical presentation of some respiratory diseases. Although massive hemoptysis accounts for a minority of all patients with hemoptysis, it is a major challenge for treatment. Massive hemoptysis has been variably defined as expectoration of 100 to more than 1000 ml of blood in 24 to 48 hours[20,21,22]. Although rare, it is a potentially lethal condition due to asphyxia and airway obstruction, shock and exsanguinations. When untreated it has a mortality rate of > 50%[23], so deserving appropriate and prompt therapeutic intervention.

In the general population, the commonest causes of massive hemoptysis are bronchiectasis and lung infections, including tuberculosis, lung abscess and aspergilloma[24]. Other causes of massive hemoptysis are lung cancer, emphysema, collagen vascular disease[22]. Aiyappan[25] referred a case of massive hemoptysis in a intravenous drug user on anticoagulants for deep vein thrombosis, with necropsy revealing the presence of bronchiectasis and pulmonary infection. On a high number of patients with massive hemoptysis it is not possible to find underlying pathology to explain the cause of the hemorrhage, and these cases are referred as "pulmonary hemorrhage syndrome"[26].

We found only two references of massive pulmonary hemorrhage associated with *Streptococcal pyogenes* pulmonary infection, both in very young children. In one of the

cases necropsy revealed the presence of numerous *cocci* in the vessels and massive pulmonary hemorrhage and isolation of group A *Streptococcus pyogenes* from the blood (type M4, T4, which produces exotoxin type B and C)[27]. The other case presented with cardio-respiratory failure and massive hemoptysis and, besides an inoperable mediastinal vascular tumor, autopsy revealed mycotic aneurysm of the superior bronchial artery[28].

On our patient the refusal of the family of the patient to accept necropsy resulted on the impossibility to know the cause of the massive hemoptysis. The low number of lymphocytes and the positive culture of pleural empyema for an atypical *Mycobacteria* was in favor of a hypothetical severe degree of previously immunodeficiency of unknown etiology. We think that this was a rational basis to accept a cause and effect relationship between the pleuropulmonary infection and the fulminant hemoptysis.

The therapeutic approach to massive hemoptysis implies urgent resuscitation, prompt diagnostic lateralization of the etiologic lesion and surgical resection if angioembolization of the pathologic bleeding arterial vessels will be not efficacious[29,30,31,32]. Unfortunately to our patient the extremely rapid worsening of the situation did not permit to proceed to any salvage therapeutic attitude.

Case 2

A 53-year-old white man with antecedents of bariatric surgery for morbid obesity in 2000 and cholecystectomy and liver fibrosis of unknown etiology was admitted on MAR 07 to our Unit, with a diagnosis of CAP with associated parapneumonic pleural effusion. The patient was an entrepreneur with business in Angola (Western Africa) and he had taken a plane to Angola already complaining of symptoms of upper respiratory viral infection lasting for four days. During the flight he suddenly feel rigors, fever (38º C), right pleuritic pain and cough with mucoid sputum, that turned purulent on the subsequent days, together with increasing dyspnoea of effort. The symptomatology did not recede with azithromycin. He came back to Portugal after 5 days, and was assisted on the day of arrival in Portugal on the Emergency Ward of our Hospital. Physical examination was in favour of acute pneumonia of right lower lobe with associated right pleural effusion. LAB tests revealed: no anemia nor thrombocytopenia, leucocytosis (17.700/mm^3) with neutrophilia (88%), PCR 24 mg/dl, normal blood biochemistry except high values of alkaline phosphatase 262 UI/L(38-126) and γ-GT 294 UI/L(15-73). The x-Ray of the thorax showed acute infection of the right lower lobe and associated voluminous pleural effusion (Fig 3). A diagnostic thoracentesis revealed serohematic pleural fluid, with low level of glucose (< 10 mg/dl), high level of protein (5.8 g/dl) and of LDH (4.600 U/L), and high number of granulocytes (total leucocytes 2.2×10^9/L with 98.5% neutrophils). He was treated empirically with e.v. ceftriaxone and clarithromycin. A first CT scan realized 48 hrs after admission revealed already some degree of loculation and an alveolar infiltrate of the lower lobe. It was decided to insert a pleurocatheter. However the degree of drainage was not enough to satisfying resolute the pleural effusion, pleural adhesions being then more exuberant,

associated with parenchymal necrosis and loculation of fluid, as was demonstrated by another CT scan 10 days later (Fig. 4). The patient was transferred to the Unit of Cardio-Thoracic Surgery of the Hospital Pulido Valente. She was submitted to surgical decortication of the lung and atypical resection of the right lower lobe. No one of the collected fluid samples, the first before surgery and the second during surgery, gave a positive result on cultural bacteriologic studies, but the patient was already taking antibiotics before sampling. The material examined at the Pathology Department was compatible with empyema. After surgery the patient initiated a program of respiratory kinesitherapy, referring progressive amelioration.

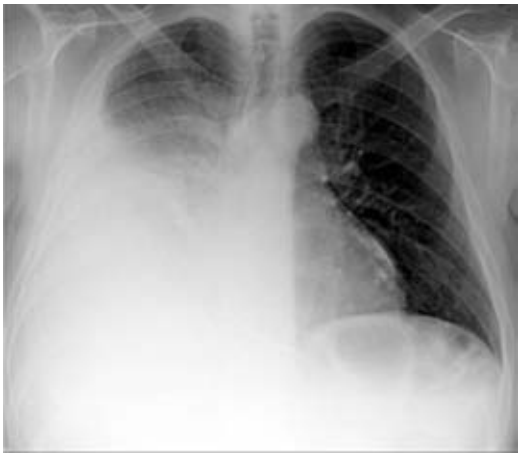

Fig. 3 – PA view of thorax X-ray showing voluminous right pleural effusion

Comment

On a report about Aircraft Cabin Air Health, Safety and Confort Challenges, Walkinshaw [33] called attention to the higher frequency of occurrence of respiratory system infections on aircraft passengers, due to several factors common in aircraft ambient: (1) high occupancy density (mostly on economy class); (2) wide range of occupant ages; (3) health conditions of the aircraft occupants; (4) activities in the aircraft during the flight; (5) pathogen strains in the environment.

A high quality and good functioning of the aircraft environment control systems of air recirculation is very important. The air in an aircraft cabin is a mixture of outside air entering the cabin (50%) and re-circulated air existent in the cabin (50%), both having to pass through filters. The filters have to remove volatile organic compounds, dust, smoke particles, bacteria and virus. A mechanism of permanent exhausting some volume of re-circulating cabin air is also working. It is also necessary to consider that cabin air circulating unintentionally through the cabin envelope can induce a number of adverse effects: condensation, corrosion, microbials, fire toxic gases[33].

Respiratory infections related to air travel is more usual during pandemics and during cold weather flu, cold and sore throat season. It is very common for air passengers suffering a sore throat or worse a few days

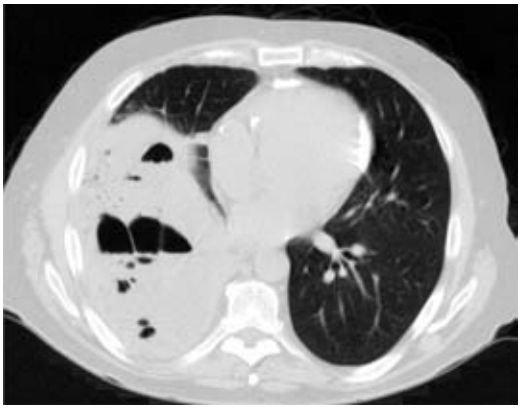

Fig. 4 – CT scan revealing loculation of the empyema

after a flying. In fact, high microbial/viral airborne concentrations were demonstrated in aircraft cabins[33].

Factors to consider responsible for the spread of respiratory infections in passengers aircraft are: (1) air circulation patterns and close seating proximity spreads pathogens between people in the same and several nearby rows, (2) multi-city and international travels increase risk, (3) high cabin occupancy density and low ventilation rate increase risk, (4) low humidity increase the risk[33].

The volume of air surrounding an office worker is typically 30 times that surrounding the occupant of a passenger aircraft. Classroom occupancy density is 10 times lower than in aircraft. The occupancy density in a cabin aircraft results in higher percentage of bioeffluents (gases, pathogens). Also the environmental control systems air delivery circulation flows cause air to circulate between occupants in the same row and in nearly rows. This circulation, plus low humidity that is more common during longer airflights, may be the main factors in the higher than "normal" upper respiratory infections[33].

Our patient was already sick, presumably with only an upper respiratory infection, but become much sicker during a long airflight, with development of pneumonia and complicated parapneumonic pleural effusion with evolution to empyema, being necessary to proceed to lung decortication for the resolution of the process.

Case 3

A 35-year-old white woman was admitted on 08 MAR 24 with a diagnosis of CAP with parapneumonic pleural effusion. For one month she had a fluctuant course of cough, hoarseness, nasal stuffiness and purulent non bloody sputum, partially alleviated with two short cycles of antibiotics. Three days before admission she complained of right pleuritic pain, tiredness and spiking fever (T 38.4 ºC). She was on thyroid replacement therapy due to hemithyroidectomy for a toxic adenoma 3 years ago. Physical examination showed no signs of respiratory failure and no haemodynamic compromise. Thoracic respiratory semiology was in favour of pneumonia of the right lower lobe and possible pleural effusion. At the Emergency Ward LAB tests revealed: slight normocytic normochromic anemia (Hb 10 g/dl), leucopenia (3.700/mm^3 with 87.5% neutrophils) and lymphopenia (451/mm^3), no thrombocytopenia, PCR 27 mg/dl, and normal biochemistry. The x-Ray of the thorax revealed moderate right pleural effusion. Empiric therapy was initiated with e.v. ceftriaxone and clarithromycin after collection of three blood cultures, that later on revealed bacteraemia by *Streptococcus pneumoniae* sensible to penicillin. Sputum culture was also positive for *Streptococcus pneumonia*. In our Unit she referred to have been separated for sometime from her husband, and meanwhile both of them had other sexual partners. At admission her CD4 count was 145/mm^3 and she had positive serology for HIV 1, with a viral charge of 2.132 copies/ml (3.33 Log 10). After several days, pleural effusion worsened (Fig 5). Thoracentesis drained purulent fluid with plenty of granulocytes and negative bacteriologic culture. CT scan of the thorax revealed voluminous right pleural empyema with two areas of

loculation (Fig. 6A), bronchiectasis of segmentary branches of the middle lobe and a lung abscess of the same lobe (Fig 6B). We proceeded to thoracic US-guided pleural fluid drainage by pleural catheter, after which the patient progressively ameliorated (Fig. 7), with discharge after 21 days of antibiotic therapy. At that time CD4 count were higher: 297/mm^3. She continued chest kinesitherapy in ambulatory and initiated HART for HIV 1 infection with efavirenz, emtricitabine and tenofovir.

Fig. 5 – PA view of thorax X-ray showing voluminous right pleural effusion and discrete densifications of the left lung

Comment

Bacterial respiratory infections, including infectious airways disease and pneumonia, currently account for most pulmonary infections diagnosed in HIV-infected individuals[34]. Two or more episodes of bacterial pneumonia within a 1-year period is considered an AIDS-defining illness in a HIV-infected patient, regardless of the CD4 cell count[35]. Besides altered cell-mediated immunity in HIV-infected patients, additional immune deficits may occur, such as poor antibody response due to B cell dysfunction and defects in chemotaxis, phagocytosis, and intracellular killing by monocytes, macrophages, and neutrophils[36]. Impairment of local defenses, expressed in depression of specific IgA at the mucosal surfaces, is another common occurrence. In HIV-infected patients all these immune abnormalities contribute to an increased risk of bacterial infection, mostly by encapsulated bacteria *Streptococcus pneumoniae* and *Haemophilus influenza*.

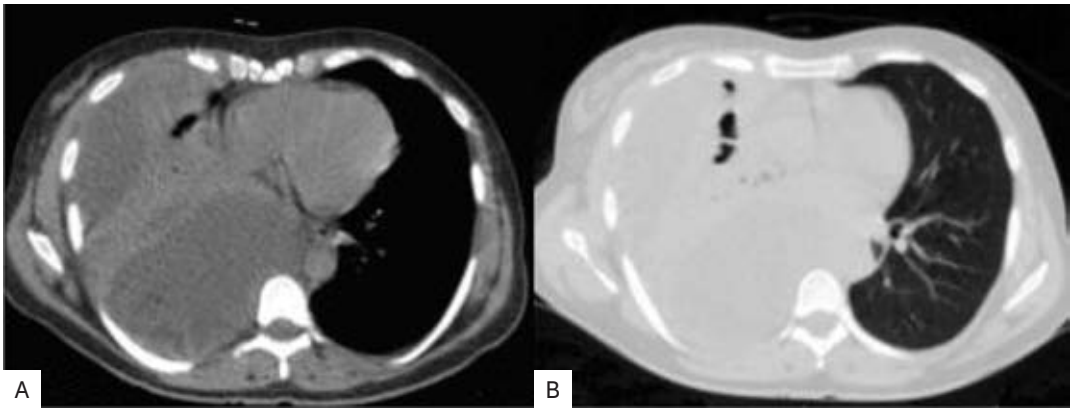

Fig. 6 – A – CT scan showing two areas of loculation of empyema; B – CT scan revealing lung abscess of the right middle lobe

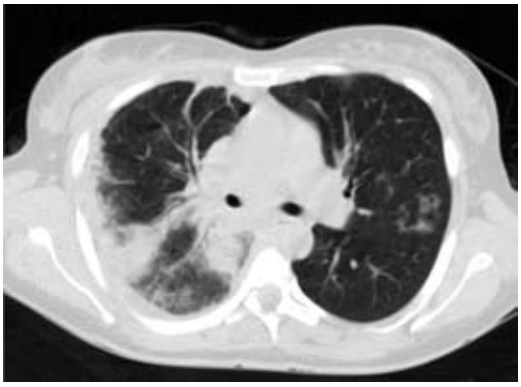

Fig. 7 – CT scan of the thorax revealing amelioration of the infectious process

The incidence of CAP in HIV-infected patients is six times greater than in the general population[37]. Depending on the degree of immune suppression different microorganisms occur with variable frequency. Although the risk of bacterial pneumonia increases steadily with declining CD4 counts, bacterial pneumonia often occurs in the early stages of HIV infection. At the initial stages of infection and besides the above referred encapsulated microorganisms, we have to consider *Staphylococcus aureus, Escherichia coli,* and *Pseudomonas aeruginosa*. Atypical agents such as *Legionella pneumophila* and *Mycoplasma pneumoniae* are not common agents in CAP in HIV patients [38]. Pleural effusion due to bacterial pneumonia occurs in greater rate in HIV patients than patients without HIV infection[39]. Also in HIV patients the clinical course is more severe, pleural fluid has a lower glucose level, there is generally a higher rate of concomitant bacteraemia (60% versus 15-30%) and positive pleural cultures, and a greater need for chest tube drainage. Bronchopleural fistula is also more frequent in these patients[40].

Depending on the type of HIV population the most common isolated agent from pleural fluid is *Streptococcus pneumonia* or *Staphylococcus aureus* (in parenteral drug abusers)[41]. Patients with HIV infection have an increased propensity for developing thoracic complex empyemas secondary to their susceptibility to polymicrobial pulmonary infections, including anaerobes[40,41], and as a consequence results of therapy with video-assisted thoracic surgery are not so favorable as in patients without HIV infection. Therefore these patients often required surgery with lung resection, which necessitated longer periods of postoperative chest tube drainage[41]. HIV-infected individuals with advanced immunosuppression are also at risk for a variety of unusual organisms, including *R. equi, N. asteroids, B. henselae* and *B. quintana*[34].

On our patient the existence of leucopenia at admission in a clinical picture of acute pneumonia lead us to suspect of coexistent infection by HIV, which was confirmed by positive serology. Bacteraemia and the complicated evolution of the parapneumonic pleural fluid in our patient was in accordance with the already known difficulties in therapeutic responses, that patients with HIV infection usually present due to multiple immunologic abnormalities.

Final discussion

The presentation of empyema can vary from nonspecific constitutional, symptoms to fulminant sepsis. Long delays in diagnosis result in delays in treatment, leading to decreased pulmonary function and local and systemic sequelae of active, ongoing infection. Early chest tube placement is impor-

tant to establish a route for drainage[43], but often it is not a definitive measure. Ashbaugh[44] refers in a review that delay in chest tube drainage increased the mortality rate from 3.4 to 16 per cent.

Parapneumonic effusions can have an evolution of a continuous spectrum of abnormalities subdivided into three stages: 1) – the exsudative stage, characterized by rapid outpouring of sterile fluid into the pleural space, that without timely correct treatment may proceed in a few days to 2) – the fibrinopurulent stage, in which extensive pleural infection decreases glucose level to values below 60 mg/dl, increases LDH to more than three times the upper normal limit for serum, pH is below 7.20 and there is high number of granulocytes. In this stage, the pleural fluid becomes progressively loculated. The effusion needs to be drained, and this becomes progressively difficult as more loculations form. Video-assisted thoracoscopic surgery is indicated to multiloculated empyema. If this is not done in due time the effusions may progress to 3) – the fibrotic stage, in which fibroblasts grow into the pleural fluid from both the visceral and parietal pleura, producing a thick pleural peel. The peel over the visceral pleura encases the lung and prevents it from expanding[5]. Because the pleural space must be eradicated if a pleural infection is going to be eliminated, this peel must be removed by decortication[45,46].

Thoracic empyema is a progressive process that does not undergo spontaneous resolution. Chronic empyema occurs when this proceed is allowed to evolve for 4 to 6 weeks without adequate treatment, consolidating into a thick fibrous peel that covers and entraps the lung. Complications of chronic empyema include costochondritis and osteomyelitis of the ribs, bronchopleural fistula, pericarditis, pulmonary and mediastinal abscesses, or disseminated infection[9].

On our Unit of Internal Medicine empyema is an entity rarely diagnosed, with an occurrence not surpassing one to two cases yearly. The admission of three cases in a year with so disparate and important characteristics, that we think can be useful to compare with cases of other patients in medical bibliography, prompted us to report these cases.

Bibliography

1. Heffner JE, Klein J. Parapneumonic effusions and empyema. Semin Resp Crit Care Med 2001; 22: 591--606.
2. Chu MA, Dewar LR, Burgess JJ, Busse EG. Empyema thoracis: lack of awareness results in a prolonged clinical course. J Canadien de Chirurgie 2001; 44: 284--288.
3. Evans AL, Gleeson FV. Radiology in pleural disease: state of the art. Respirology 2004; 9: 300-312.
4. Ahmed RA, Marrie TJ, Huang JQ. Thoracic empyema in patients with community-acquired pneumonia. Am J Med 2006; 119: 877-883.
5. Light RW. Parapneumonic effusions and empyema. Proceedings Am Thor Soc 2006; 3: 75-80.
6. Coote N, Kay E. Surgical versus non-surgical management of pleural empyema. Cochrane Database Syst Rev 2005; 19(4): CD001956.
7. Luh SP, Chou MC, Wang LS, Chen JY, Tsai TP. Video-assisted thoracoscopic surgery in the treatment of complicated parapneumonic effusions or empyemas: outcome of 234 patients. Chest 2005; 127: 1427--1432.
8. Chen K-Y, Hsueh PR, Liaw YS, Yang PC, Kuh KT. A 10-year experience with bacteriology of acute thoracic empyema: emphasis on Klebsiella pneumonia in patients with diabetes mellitus. Chest 117: 1685-1689.
9. Martella AT, Santos GH. Decortication for chronic postpneumonic empyema. J Am Coll Surg 1995; 180: 573-576.
10. Sharma S, Harding G. Streptococcus group A infections. In Internet: http://www.emedicine.com/med/topic2184.htm.

11. Johnson JL. Pleurisy, fever, and rapidly progressive pleural effusion in a healthy, 29-year-old physician. Chest 2991; 119: 1266-1269.
12. Basilière JL, Bistrong HW, Spence WF. Streptococcal pneumonia. Recent outbreaks in military recruit populations. Am J Med 1968; 44: 580-589.
13. Muller MP, Low DE, Green KA, Simor AE, Loeb M, Gregson D, *et al.* Clinical and epidemiological features of group A streptococcal pneumonia in Ontario, Canada. Arch Int Med 2003; 163: 467-472.
14. McMurray JJ, Fraser DM. Fatal Streptococcus pyogenes pneumonia. J Royal Soc Med 1987; 80: 525-6.
15. Buckingham SC, King MD, Miller ML. Incidence and etiologies of complicated parapneumonic effusions in children, 1966 to 2001. Pediatr Infect Dis 2003; 22: 499-504.
16. Thaarup J, Ellerman-Eriksen S, Stjernholm J. Neonatal pleural empyema with group A streptococci. Acta Pediatr 1997; 86: 769-771.
17. Barnham M, Weightman NC, Anderson AW, Pagan FS, Chapman ST. Review of 17 cases of pneumonia caused by *Streptococcus pyogenes*. Euro J Clin Microbiol Infect Dis 1999; 18: 506-509.
18. Mohanty S, Das BK, Kapil A. Pleural empyema due to a group A beta-hemolytic streptococci in an adult. Indian J Med Sci 2005; 59: 213-214.
19. Khatib R, Siwick J. Pyopneumothorax: a complication of *Streptococcus pyogenes* pharyngitis. Scand J Infect Dis 2000; 32: 564-565.
20. Guimaraes CA. Massive hemoptysis. *In* Pearson FG, (Ed.). Thoracic Surgery. Churchill Livingstone; USA, 1995: 581-585.
21. Johnson JL. Manifestations of haemoptysis. How to manage minor, moderate, and massive bleeding. Postgrad Med 2002; 112: 101-113.
22. Metin M, Sayar A, Turna A, Solak O, Erkan L, Dinçer SI, *et al.* Emergency surgery for massive haemoptysis. Acta Chir Belg 2005; 105: 639-643.
23. Stoll JF, Bettmen M. Bronchial artery embolization to control haemoptysis: a review. Cardiovasc Interv Radiol 1988; 11: 263-269.
24. Ashraf O. Hemoptysis, a developing world perspective. BMC Pulm Med 2006; 6: 1.
25. Aiyappan V, Muthiah M. Massive haemoptysis in intravenous drug users: Case report and review of the literature. Ann Thor Med 2997; 2: 36.
26. Capron F. Pulmonary hemorrhage syndromes. *In:* Haselton PS (Ed.). Spencer's pathology of the lung. 5th ed. McGraw-Hill Co.; USA, 1996:865-874.
27. Nakada H, Maemoto T, Kitazawa K, Honda A, Shimuzu Y, Ooe K. Fulminant group A streptococcal infection accompanied by massive pulmonary hemorrhage and subsequent asphyxia. A case report. Kasenshogaku Zasshi 1994; 68: 1428-1432 (in Japanese; abstract in English).
28. Chantepie A, Robert M, Pelletier, Gold F, Mercier C, Lacombe A, *et al.* Mycotic aneurism of bronchial artery. A propos of a case in an infant. Chir Pediatr (French) 1980; 21: 407-410.
29. Enting D, van der Werf TS, Prins TR, Zijlstra JG, Lightenberg JJ, Tulleken JE. Massive hemoptysis: primary care, diagnosis and treatment. Ned Tijdschr Geneeskd 2004; 148: 1582-1586.
30. Ong TH, Eng P. Massive hemoptysis requiring intensive care. Intensive Cre Med 2003; 29: 317-320.
31. Swanson KL, Johnson CM, Prakash UB, *et al.* Bronchial artery embolization: Experience with 54 patients. Chest 2002; 121: 789-795.
32. Gourin A, Garzon AA. Operative treatment of massive hemoptysis. Ann Thorac Surg 1974; 18: 52-60.
33. Walkinshaw DS. Passenger aircraft indoor air quality challenges and solutions II: Presentation to the ASHRAE Ottawa Valley Chapter Meeting 2008. Internet: Walkinshaw@indoorair.ca
34. Brecher CW, Aviram G, Boiselle PM. CT and radiography of bacterial respiratory infections. AJR 2003; 180: 1203-1209.
35. Centers for Disease Control. 1993 revised classification system for hiv infection and expanded surveillance case definition for AIDS among adolescents and adults. Morb Mortal WKLY Rep 1992; 41: 1-19.
36. Noskin GA, Glassroth J. Bacterial pneumonia associated with HIV-1 infection. Clin Chest Med 1996; 17: 713-7723.
37. Hirschtick RE, Glassroth J, Jordan MC, *et al.* Bacterial pneumonia in persons infected with the human deficiency virus. New Engl J Med 1995; 333: 845--851.
38. Rimland D, Navin TR, Lennox JA, *et al.* Prospective study of etiologic agents of community acquired pneumonia in HIV infection. AIDS 2002; 16: 85-95.
39. Joseph J, Strange C, Sahn SA. Pleural effusions in hospitalized patients with AIDS. Ann Int Med 1993; 118: 856-859.
40. Borge JH, Michavila IA, Mendez JM, Rodriguez FC, Grinan NP, Cerrato RV. Thoracic empyema in HIV-infected patients: Microbiology, management and outcome. Chest 1998; 113: 732-738.
41. Suay VG, Cordero PJ, Martínez E, Soler JJ, Perpiñá M, Greses JV, *et al.* Parapneumonic effusions secondary to community-acquired bacterial pneumonia in human

immunodeficiency virus-infected patients. Eur Resp J 1995; 8: 1934-1939.
42. Khwaja S, Rosenbaum DH, Paul MC, Bhojani RA, Estrera AS, Wait MA, *et al.* Surgical treatment of thoracic empyema in HIV-infected patients: severity and treatment modality is associated withCD4 count status. Chest 2005; 128: 246-249.
43. Lee-Chiong TL Jr. Treating empyema without surgery. Postgraduate Med 1997; 101: 195-204.
44. Asbaugh DG. Empyema thoracis, factors influencing morbidity and mortality. Chest 1991; 99: 1162--1165.
45. Andrews NC, Parker EF, Shaw RR, Wilson NJ, Webb RR. Management of nontuberculous empyema. Am Rev Resp Dis 1962; 85: 935-936.
46. Pothula V, Krellenstein DJ. Early aggressive surgical management of parapneumonic empyemas. Chest 1994; 105: 832-836.