

Hepaticoduodenostomy in Combined Endoscopic Ultrasound-Endoscopic Retrograde Cholangiopancreatography Biliary Drainage for Malignant Hilar Biliary Obstruction

Diogo Bernardo Moura Nuno Nunes Carolina Chálim Rebelo
Francisca Côrte-Real Nuno Paz Maria Antónia Duarte

Gastroenterology Department, Hospital do Divino Espírito Santo de Ponta Delgada EPER, Ponta Delgada, Portugal

Keywords

Combination of endoscopic ultrasound and endoscopic retrograde cholangiopancreatography · Hepaticoduodenostomy · Malignant hilar biliary obstruction

Hepatoduodenostomia em drenagem biliar combinada por EUS-CPRE para obstrução biliar hilar maligna

Palavras Chave

Combinação de ecoendoscopia e colangiopancreatografia retrógrada endoscópica · Hepatoduodenostomia · Obstrução biliar hilar maligna

Endoscopic ultrasound biliary drainage (EUS-BD) has been increasingly used in the management of malignant biliary obstruction together with endoscopic retrograde cholangiopancreatography (ERCP). Drainage of $\geq 50\%$ of hepatic volume is associated with an increase in survival and lesser risk of cholangitis, and bilateral drainage in hilar stenosis results in fewer reinterventions [1, 2]. When the left biliary system is drained through the papilla, EUS-guided hepaticoduodenostomy (EUS-HDS) is a difficult

procedure that can be used to access the right system [3]. Combination of EUS-BD and ERCP (CERES) is in increasing development, particularly when the left and right biliary systems are noncommunicating [3, 4]. The authors present a case of EUS-HDS in the right hepatic duct combined with left hepatic duct stenting by ERCP in malignant hilar biliary obstruction (Fig. 1; online suppl. video; for all online suppl. material, see <https://doi.org/10.1159/000530977>).

A 60-year-old female patient with unresectable cholangiocarcinoma and hilar stricture (Bismuth type IV), with previous drainage of a technically difficult stricture of the left hepatic duct with a plastic stent, developed obstructive jaundice due to disease progression, incompatible with palliative chemotherapy. An ERCP was performed with plastic stent replacement in the left hepatic duct (Fig. 2a). Right hepatic duct stenting was not possible due to impossibility of passing a guidewire; cholangioscopy assistance was assumed to provide no further benefit because we were facing a very tight stricture, so EUS-BD was performed. EUS showed a dilated right hepatic duct (7.4 mm) (Fig. 2b). The right hepatic duct was punctured (Expect™ 19 G, Boston Scientific, Boston, USA), with confirmation by cholangiography (Fig. 3a). After guidewire introduction through the puncture site (Jagwire™ 0.0025", Boston

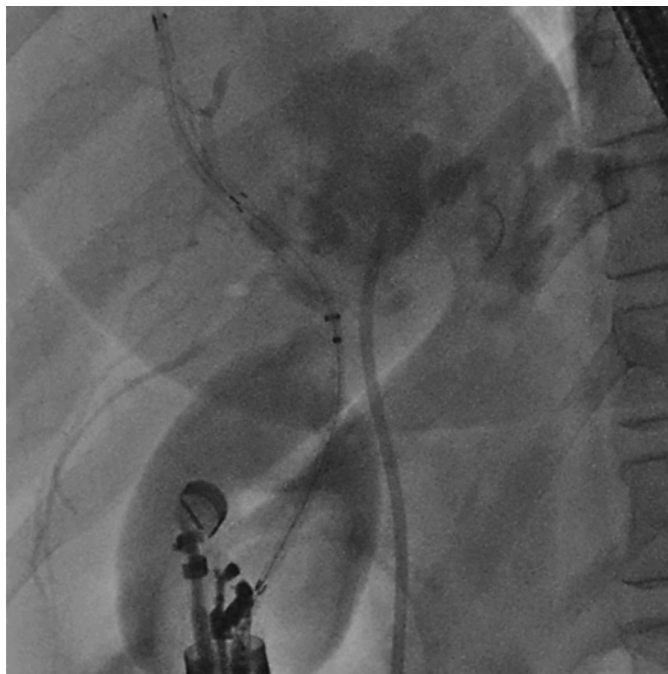


Fig. 1. Combined EUS-BD and endoscopic retrograde cholangiopancreatography in a malignant hilar biliary obstruction, restenting the left hepatic duct and hepaticoduodenostomy on the right hepatic duct, achieving bilateral drainage. EUS: after guidewire introduction, a hybrid metallic stent was placed between the right hepatic duct and the duodenal bulb.

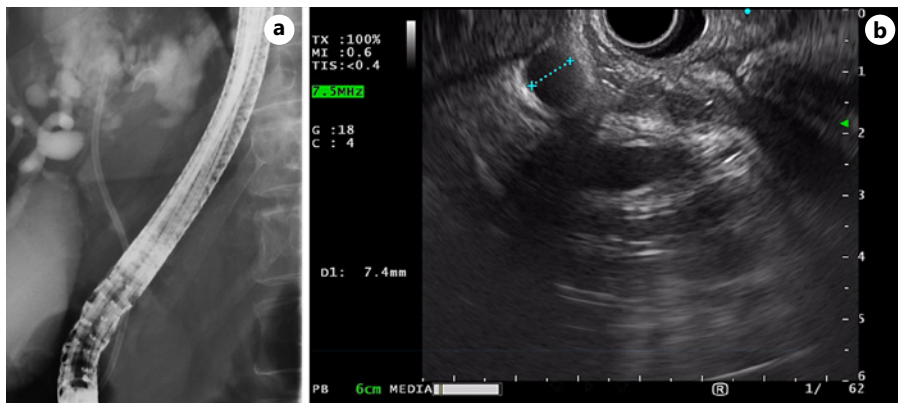


Fig. 2. **a** Cholangiography after plastic stent replacement in the left hepatic duct. **b** Dilated right hepatic duct.

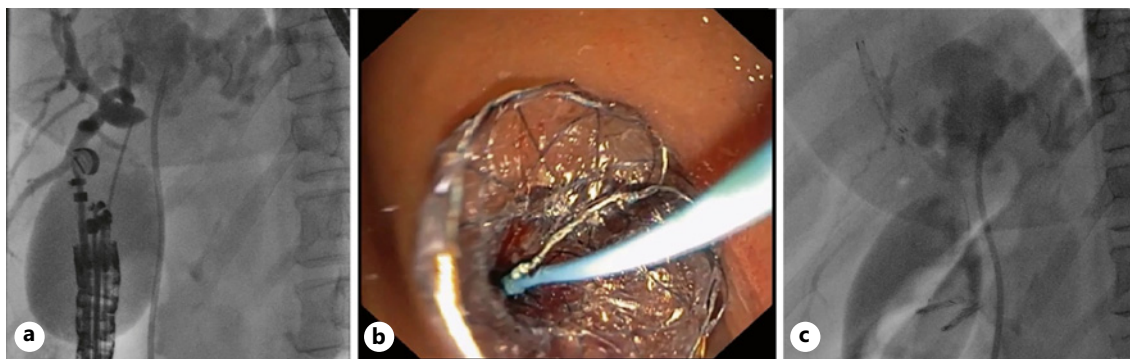


Fig. 3. **a** Right hepatic duct puncture confirmation by cholangiography. **b** Hybrid metallic stent placement between the right hepatic duct and the duodenal bulb. **c** Cholangiography after bilateral biliary drainage with hepaticoduodenostomy in the right hepatic duct and plastic stent on the left hepatic duct.

Scientific, Boston, USA), the needle was retrieved and a hybrid metallic stent (BPD HANAROSTENT® biliary [NC], 10*80 mm, M.I.Tech, Pyeongtaek-si, Gyeonggi-do, Republic of Korea) was placed between the right hepatic duct and the duodenal bulb (Fig. 3b, c). The stent delivery system was passed through the puncture site without the need of using a cautery or balloon dilation to create the tract. The uncovered intra-hepatic segment of the stent prevents stent migration; to further minimize the risk of migration, two through-the-scope clips (Resolution™, Boston Scientific, Boston, USA) were applied on the duodenal extremity. No adverse events were observed. Jaundice resolved, with no need for further procedures during the follow-up of 5 months.

Percutaneous transhepatic biliary drainage (PTBD) could be an alternative to EUS-HDS in the present case. PTBD requires an external drainage which disrupts the patient's quality of life, making CERES an internal and elegant solution. Preliminary data of the clinical outcomes of CERES in malignant hilar biliary obstruction have shown significantly lower recurrent biliary obstruction rates compared to PTBD, with a similar complication rate and no significant mortality difference [4, 5].

Statement of Ethics

Ethical approval was not required for this study in accordance with local/national guidelines. Written informed consent

References

- 1 Khoo S, Do N, Kongkam P. Efficacy and safety of EUS biliary drainage in malignant distal and hilar biliary obstruction: a comprehensive review of literature and algorithm. *Endosc Ultrasound*. 2020;9(6):369–79.
- 2 Dumonceau J, Tringali A, Papanikolaou I, Blero D, Mangiavillano B, Schmidt A, et al. Endoscopic biliary stenting: indications, choice of stents, and results: European society of gastrointestinal endoscopy (ESGE) clinical guideline – updated october 2017. *Endoscopy*. 2018;50(9):910–30.
- 3 Sundaram S, Dhir V. EUS-guided biliary drainage for malignant hilar biliary obstruction: a concise review. *Endosc Ultrasound*. 2021;10(3):154–60.
- 4 Kongkam P, Tasneem A, Rerknimitr R. Combination of endoscopic retrograde cholangiopancreatography and endoscopic ultrasonography-guided biliary drainage in malignant hilar biliary obstruction. *Dig Endosc*. 2019;31(Suppl 1):50–4.
- 5 Kongkam P, Orprayoon T, Boonmee C, Sodarath P, Seabmuangsai O, Wachiramatharuch C, et al. ERCP plus endoscopic ultrasound-guided biliary drainage versus percutaneous transhepatic biliary drainage for malignant hilar biliary obstruction: a multicenter observational open-label study. *Endoscopy*. 2021; 53(1):55–62.

was obtained from the patient for publication of this case report and any accompanying images, according to Helsinki Declaration.

Conflict of Interest Statement

The authors have no conflicts of interest to declare.

Funding Sources

The authors have no funding sources to declare.

Author Contributions

Diogo Bernardo Moura: article concept, literature review, and drafting of the manuscript. Nuno Nunes: main endoscopist of the described procedure, literature review, and critical review of the manuscript. Carolina Chálim Rebelo, Francisca Côrte-Real, Nuno Paz, and Maria Antónia Duarte: critical review of the manuscript.

Data Availability Statement

All data generated or analyzed during this study are included in this case report and its online supplementary material. Further inquiries can be directed to the corresponding author.