

Silent Multiple Lymphomatous Polyposis in Mantle Cell Lymphoma: From the Ileum to the Stoma

Sofia Bragança^a André Pereira^b Gonçalo Alexandrino^a Filipa Moita^c
Mariana Nuno Costa^a David Horta^a

^aGastroenterology Department, Hospital Prof. Doutor Fernando Fonseca, Amadora, Portugal; ^bAnatomic Pathology Department, Hospital Prof. Doutor Fernando Fonseca, Amadora, Portugal; ^cHematology Department, Instituto Português de Oncologia de Lisboa Francisco Gentil, Lisboa, Portugal

Keywords

Colonoscopy · Multiple lymphomatous polyposis · Mantle cell lymphoma

Polipose Linfomatosa Múltipla Silenciosa No Linfoma de Células Do Manto: Desde o Íleon Até Ao Estoma

Palavras Chave

Colonoscopia · Polipose linfomatosa múltipla · Linfoma de células do manto

We present the case of a 79-year-old male with known history of sigmoid colon cancer, diagnosed in the context of bowel obstruction in 2018. In that setting, he was submitted to an emergent Hartmann procedure, maintaining the colostomy ever since. After staging (IIIB AJCC classification), the patient completed 6 months of adjuvant chemotherapy (CT). The first and last colonoscopy was 6 months after surgery. No relapse was noticed during the surveillance period. Three years later, he developed oropharyngeal dysphagia, without any other gastrointestinal symptoms. Physical examination showed an asymmetric tonsillar hypertrophy and multiple soft and

painless cervical adenomegalies. He was referred to otorhinolaryngology and hematology at a cancer center. The tonsil biopsy showed a classic mantle cell lymphoma (MCL), and the chromosomal translocation t(11; 14) was identified by fluorescence in situ hybridization technique. The staging computerized tomography scan revealed adenopathies above and below the diaphragm, a large cecal mass (shown in Fig. 1c), and a heterogeneous appearance of the colic and ileal mucosa (shown in Fig. 1a, b). A total colonoscopy was performed, and, between the colostomy and the terminal ileum, multiple polyps were identified (shown in Fig. 2a–c and Fig. 2e), some of them with central umbilication. In addition, a vegetating mass measuring 55 mm in diameter was observed in the cecum (shown in Fig. 2d). Biopsies of the polyps in the ileum, ascending and descending colon, as well as cecal mass were performed, and, in all of them, pathology showed a monomorphic lymphoid cell infiltrate (shown in Fig. 3a). The lymphoid cells stained positive for CD20 and CD5 and negative for CD3 (shown in Fig. 3b). In addition, cyclin-D1 nuclear overexpression was observed (shown in Fig. 3c). The patient was diagnosed with an MCL stage IVA (Ann-Arbor classification), with a high-risk MIPIb score. After completing 2 cycles of R-bendamustine

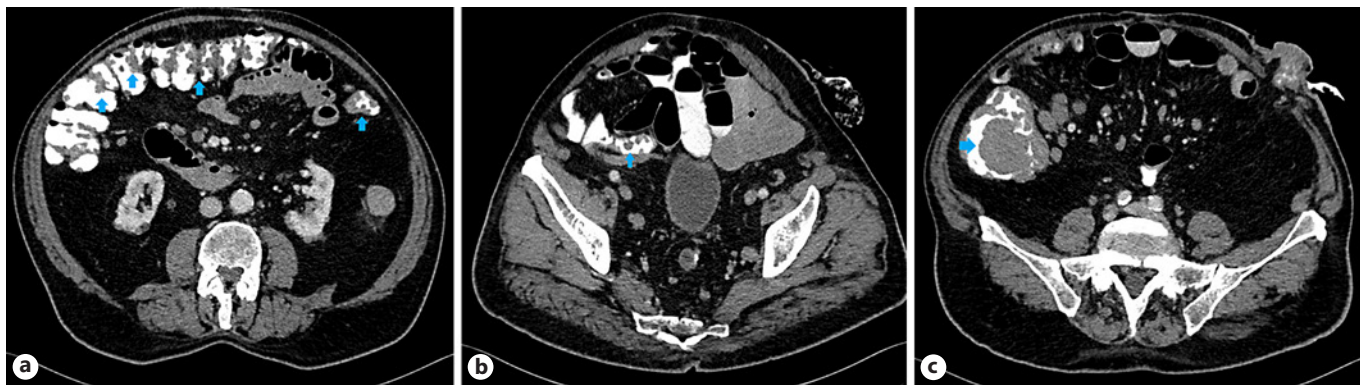

Fig. 1. Computerized tomography scan showing heterogeneous changes in colic mucosa (blue arrows) (a) and in terminal ileum (blue arrows) (b). c Cecal mass (blue arrows).

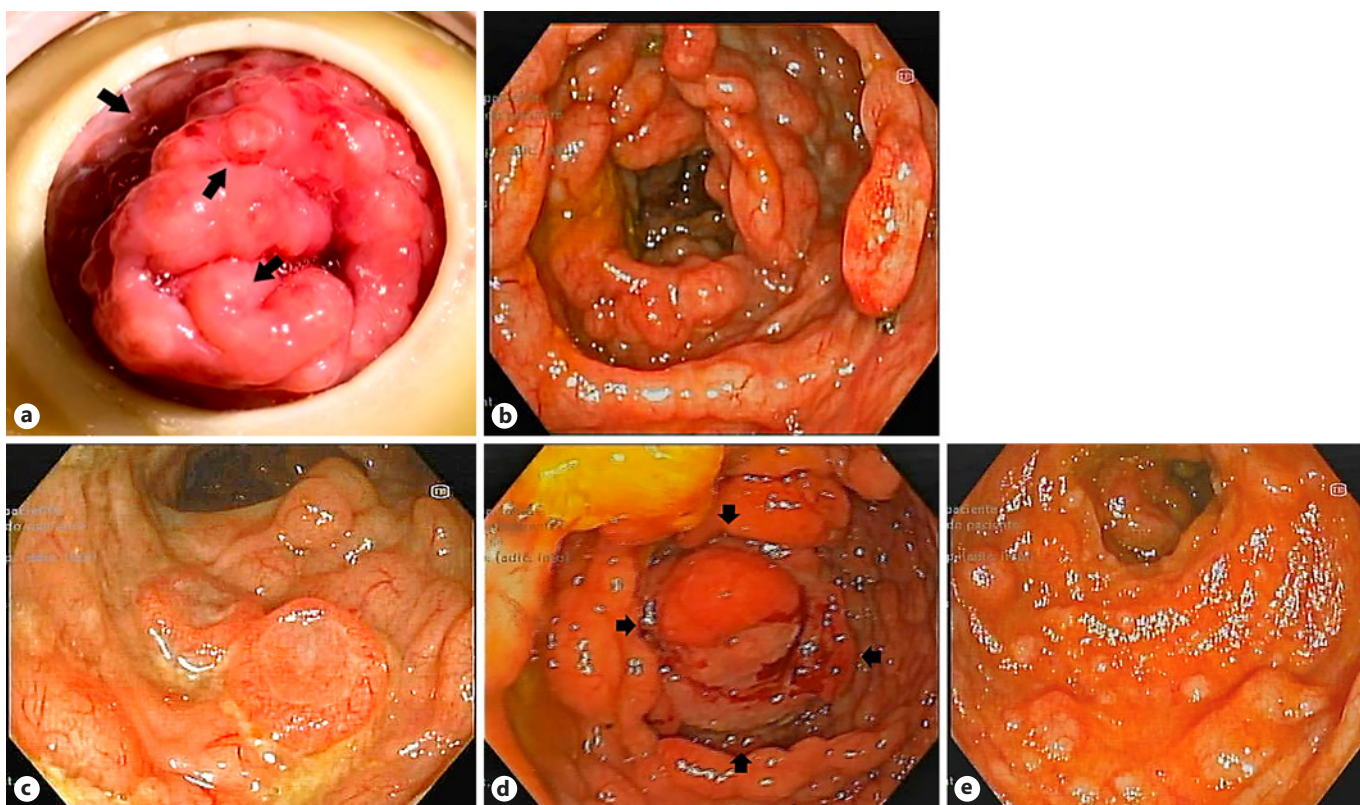


Fig. 2. Colonoscopy findings showing colostomy orifice with polyps on the surface (black arrows) (a); colon with multiple polyps (b); polyp with central umbilication (c); vegetating cecal mass – outlined by black arrows (d); terminal ileum with multiple polyps (e).

(rituximab and bendamustine), he was diagnosed with COVID-19, and CT was suspended. The MCL remained stable while waiting for virologic cure. The patient restarted CT with R-CVP (rituximab, cyclophosphamide,

vincristine, prednisolone), and a reevaluation colonoscopy will be performed at the end of 6th CT cycle.

This case illustrates a silent presentation of an exuberant entity: multiple lymphomatous polyposis (MLP).

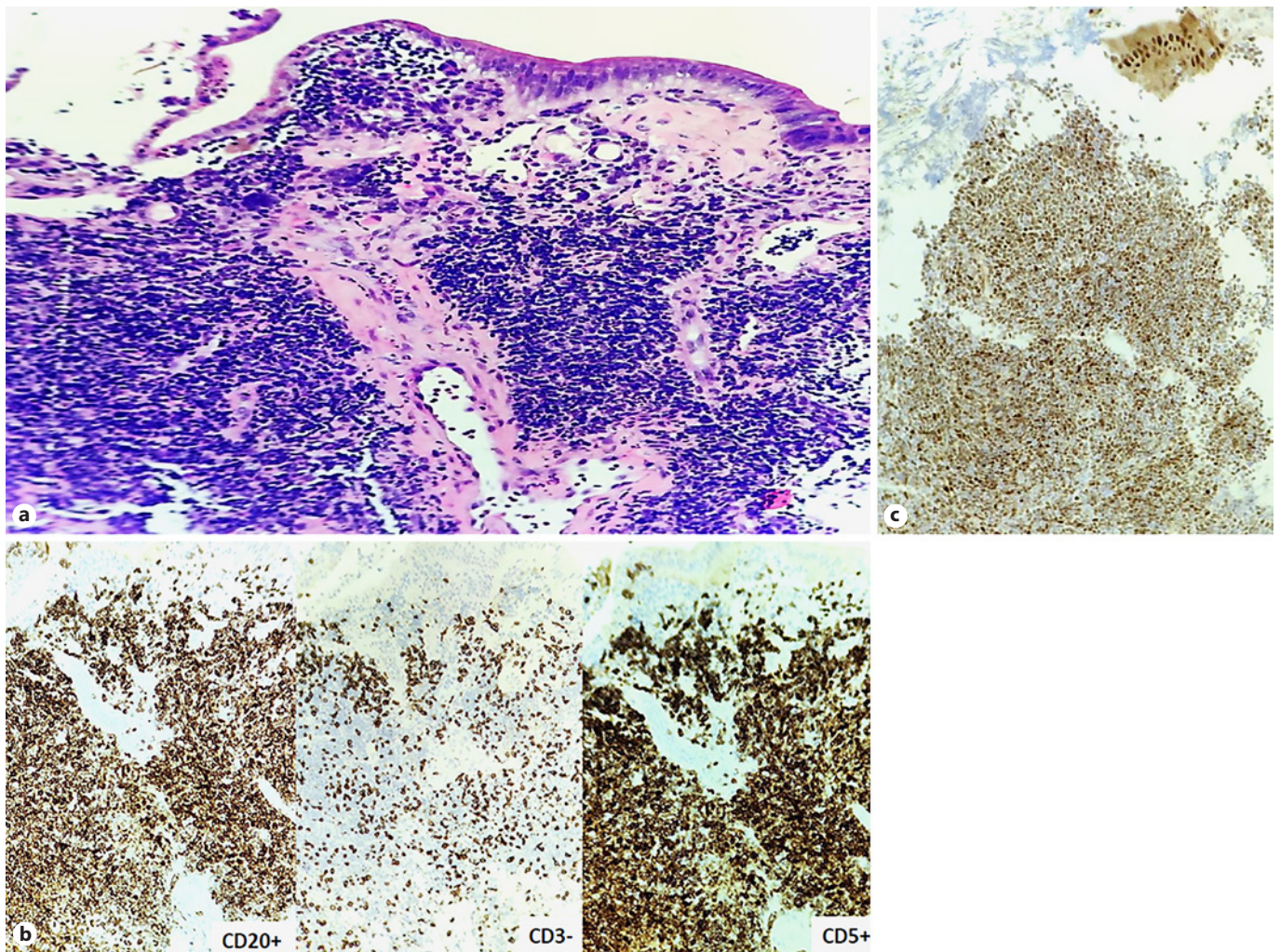


Fig. 3. Anatomopathological findings showing H&E $\times 100$ showing a monomorphic lymphoid cells infiltrate (a); immunohistochemistry $\times 100$ – staining positive for CD5 and CD20 and negative for CD3 (b); and overexpression of cyclin-D1 ($\times 100$) (c).

MCL represents 6% of all non-Hodgkin lymphomas and is characterized by the chromosomal t(11; 14) which results in cyclin-D1 overexpression. The MCL affects mostly males in their 60–70 years and usually presents with disseminated disease, as seen in our patient [1]. Previously, gastrointestinal involvement was described in about 30% of the cases; however, it may be underestimated given the evidence of only microscopic involvement of the colon in about 84% of patients [2]. MLP is the most frequent colonic endoscopic finding of MCL, although isolated polyps or masses can also be found [3]. Besides lymphoma, the main differential diagnosis of MLP is intestinal pneumatosis. In younger patients, polyposis syn-

dromes and inflammatory bowel disease should also be considered [4]. Regarding MCL treatment, the R-bendamustine regimen has the higher 5-year progression-free survival (65.5% vs. 55.8%), but the R-CVP regimen confers less immunosuppression [5].

Statement of Ethics

Ethical approval was not required for this study in accordance with local/national guidelines. Written informed consent was obtained from the patient, authorizing the publication of the clinical case and images, according to the Declaration of Helsinki.

Conflict of Interest Statement

The authors have no conflict of interests to declare.

Funding Sources

The authors have no funding sources to declare.

Data Availability Statement

The data on this case report are not published anywhere because they contain information that may compromise the privacy of the patient, but they may be available if requested to Sofia Bragança.

References

- 1 Ruskoné -Fourmestraux A, Delmer A, Lavergne A, Molina T, Brousse N, Audouin J, et al. Multiple lymphomatous polyposis of the gastrointestinal tract: prospective clinicopathologic study of 31 cases. Groupe D'étude des Lymphomes Digestifs. *Gastroenterology*. 1997;112(1):7–16.
- 2 Romaguera JE, Medeiros LJ, Hagemester FB, Fayad LE, Rodriguez MA, Pro B, et al. Frequency of gastrointestinal involvement and its clinical significance in mantle cell lymphoma. *Cancer*. 2003 Feb 1;97(3):586–91.
- 3 Lee HH, Cho SG, Lee IS, Cho HJ, Jeon YW, Hyun JO, et al. Mantle cell lymphoma with gastrointestinal involvement and the role of endoscopic examinations. *PLoS One*. 2020 Sep 1;15(9):e0239740.
- 4 Aisa P, Añorbe E, de Ormijana JS, Paraíso M. Multiple lymphomatous polyposis. *Euro J Radiol Extra*. 2003;46(1):14–6.
- 5 Flinn IW, van der Jagt R, Kahl B, Wood P, Hawkins T, Macdonald D, et al. First-line treatment of patients with indolent non-hodgkin lymphoma or mantle-cell lymphoma with bendamustine plus rituximab versus R-CHOP or R-CVP: results of the BRIGHT 5-year follow-up study. *J Clin Oncol*. 2019; 37(12):984–91.

Author Contributions

Sofia Bragança obtained the data, wrote the manuscript, and reviewed the literature. André Pereira reviewed the histopathological findings and provided the histopathological images as well as explanation. Filipa Moita provided clinical data on the diagnosis and treatment of lymphoma as well critical revision of the manuscript. Gonçalo Alexandrino, Mariana Nuno Costa, and David Horta were responsible for critical revision of the manuscript. All authors approved the published version of the manuscript.