

# Primary Diffuse Large B-Cell Lymphoma of the Rectum in a Non-Immunosuppressed Patient with Ulcerative Colitis

Sofia Saraiva<sup>a</sup> Sónia Bernardo<sup>b</sup> Samuel Fernandes<sup>b</sup> Pedro Costa<sup>b</sup>  
Luis Correia<sup>b</sup> Rui Tato Marinho<sup>b</sup>

<sup>a</sup>Gastroenterology Department, Instituto Português de Oncologia de Lisboa Francisco Gentil, Lisbon, Portugal;

<sup>b</sup>Gastroenterology and Hepatology Department, Centro Hospital Universitário de Lisboa Norte – Hospital de Santa Maria, Lisbon, Portugal

## Keywords

Diffuse large B-cell lymphoma · Ulcerative colitis · Epstein-Barr virus

## Abstract

**Introduction:** The incidence of primary colorectal lymphoma in the gastrointestinal tract is very low, the rectum being infrequently affected. The development of this entity in inflammatory bowel disease patients usually occurs in a context of immunosuppression-based therapy, with only a few case reports describing its development in patients presenting no known risk factors. Moreover, the clinical presentation of primary colorectal lymphomas may be difficult to distinguish from an acute flare of ulcerative colitis (UC). **Case Presentation:** We present a case of non-Hodgkin lymphoma of the rectum in a 42-year-old male with a 7-year history of UC and no previous exposure to immunomodulatory agents. He presented with a history of mucous diarrhoea, tenesmus, proctalgia and weight loss, refractory to optimized therapy. A lower gastrointestinal endoscopy was performed revealing a circumferential ulcerated lesion of the rectum, from which histopathological analysis established the diagnosis of a non-Hodgkin diffuse large B-cell lymphoma (DLBCL).

**Discussion/Conclusion:** The present case suggests the existence of alternative mechanisms for the development of DLBCL in UC patients. The clinical presentation mimicking an acute flare of UC posed a diagnostic challenge, highlighting the complexity behind the management of UC patients.

© 2022 Sociedade Portuguesa de Gastrenterologia.  
Published by S. Karger AG, Basel

**Linfoma difuso de grandes células B primário do reto em doente com colite ulcerosa sem terapêutica imunossupressora**

## Palavras Chave

Linfoma difuso de grandes células B · Colite ulcerosa · Vírus Epstein-Barr

## Resumo

**Introdução:** O linfoma não *Hodgkin* (LNH) difuso de grandes células B (DGCB) colorretal primário é uma entidade rara, estando a sua associação com a colite ulcerosa (CU) relacionada com a exposição a imunomoduladores. Apresentamos uma forma particularmente rara de LN-

HDGCB primário, com atingimento do reto em doente com proctite ulcerosa sem história de imunossuppressores, cuja apresentação simula agudização da CU. **Descrição do caso clínico:** Homem de 42 anos, com diagnóstico de proctite ulcerosa desde 2014, e sem história de terapêutica imunossupressora. Inicia quadro de diarreia com muco, proctalgia intensa, tenesmo e perda ponderal (10% em 2 meses), sem melhoria após otimização da terapêutica. Realiza colonoscopia que revela lesão ulcerada e circunferencial a nível do reto, condicionando estenose luminal, cujas biopsias revelaram LNHDGCB. **Discussão/Conclusão:** O presente caso sugere a existência de mecanismos fisiopatológicos alternativos à terapêutica imunossupressora para o desenvolvimento de LNH em doentes com CU. A apresentação clínica sugestiva de agudização da CU, constituiu um verdadeiro desafio diagnóstico, fazendo realçar a complexidade da abordagem destes doentes.

© 2022 Sociedade Portuguesa de Gastroenterologia.  
Publicado por S. Karger AG, Basel

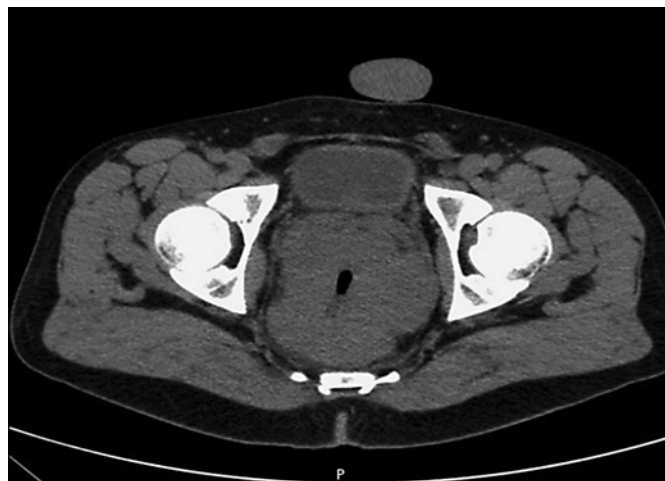## Introduction

Primary colorectal lymphoma is a very rare condition, accounting for 0.2% of all colorectal malignancies [1–3]. Its association with ulcerative colitis (UC) is mainly related to the use of immunomodulators, which dictate a definite increase in risk of lymphoproliferative disorders (LDs). In the absence of immunosuppressive therapy, the risk of LD in inflammatory bowel disease (IBD) patients seems to be similar to that of the general population [4]. Herein we describe a case of a particularly rare form of diffuse large B-cell lymphoma (DLBCL), with rectal involvement, in a patient with ulcerative proctitis with no history of immunomodulator exposure. The disease presentation simulated an acute flare of the patient's chronic disease.

## Case Report

We present the case of a 42-year-old male with a 7-year history of ulcerative proctitis treated with topical mesalamine (suppository 1 g/day) and no previous exposure to immunomodulatory agents or corticosteroids. His medical history was uneventful. He had a family history of IBD but no history of neoplasia or LD. In the last colonoscopy, performed in March 2019, the patient was in endoscopic remission (Mayo subscore 0).

In September 2020 the patient developed diarrhoea with 3–4 bowel movements per day, the stools consisting of watery fluids and mucus, without blood. Three months later, symptoms persisted despite intensive topical and oral treatment with mesala-

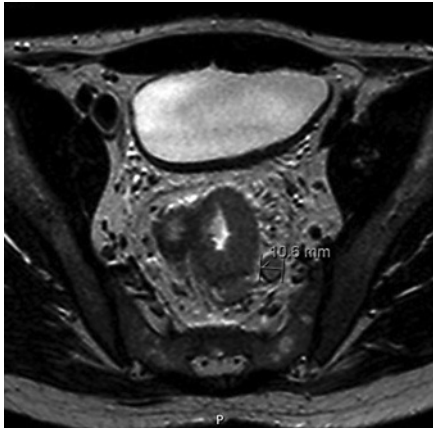

**Fig. 1.** Abdominal CT scan showing circumferential stricturing lesion located at the lower/mid rectum with associated wall thickening.

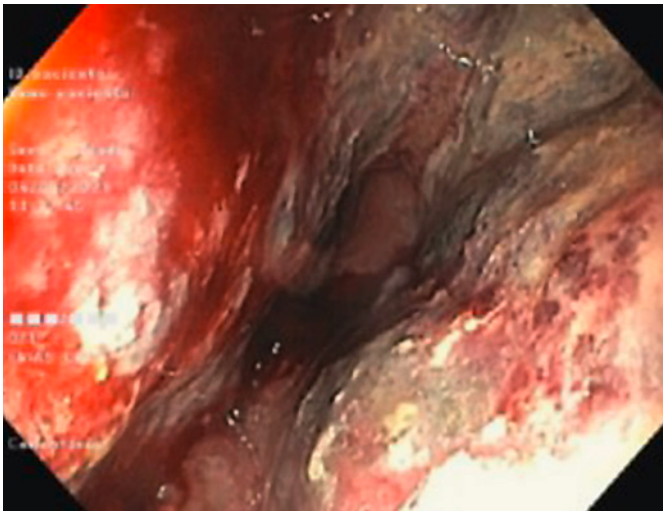
mine (suppository 1 g/day + oral mesalamine 4.5 g/day). At this time, the patient also complained of severe rectal pain, tenesmus and weight loss (10% in 2 months). He denied fever, fatigue or night sweats. Topical budesonide was prescribed without improvement. Oral prednisolone was then started, and colonoscopy performed, revealing a suspicious rectal lesion. The patient was admitted to the hospital to proceed with the investigation and for pain management.

At admission, the patient complained of severe rectal pain, only controlled with tramadol perfusion. On physical examination, the patient was haemodynamically stable and had no fever. There were no enlarged palpable lymph nodes. Abdominal examination did not show any signs of tenderness or palpable masses, but on rectal examination, a palpable firm mass was detected. Blood tests revealed a slightly elevated C-reactive protein (1.17 mg/dL) with normal white blood cell count ( $10.9 \times 10^9/L$ ). Abdominal X-ray was normal. An urgent computed tomography (CT) revealed the presence of a circumferential lesion located at the lower/mid rectum with associated wall thickening. Significant luminal narrowing was also described (Fig. 1). A pelvic magnetic resonance imaging (MRI) was further conducted, showing a concentric circumferential rectal wall thickening with ulceration beginning at 3 cm from the anal verge and extending longitudinally along 12 cm. This mass invaded the mesorectal fascia and the right sphincter complex, having a defined cleavage plane with the prostate and bladder. Regional lymph node involvement was observed (Fig. 2).

Complementary laboratory studies were obtained; namely, tests for sexually transmitted diseases, including human immunodeficiency virus (HIV) types 1 and 2, herpes simplex virus (HSV) type 2, *Chlamydia trachomatis* and *Treponema pallidum*, were negative; serology for HSV type 1 and *Cytomegalovirus* revealed the presence of specific IgG antibodies; serological marker for hepatitis C virus (HCV) was negative and hepatitis B surface antibody was detected for hepatitis B virus (HBV). Evaluation of the Epstein-Barr virus (EBV)-specific antibody profile revealed positivity for IgG with equivocal IgM. The viral load measurement was fur-



**Fig. 2.** Pelvic MRI confirmed the presence of rectal wall thickening with ulceration extending from 3 to 12 cm above the anal verge. Regional lymph node involvement was also observed.



**Fig. 3.** Colonoscopy showing circumferential and extensively ulcerated lesion of the rectum, with associated stenosis.

ther added to the study, confirming the presence of an acute infection (5,972 copies/mL).

A lower gastrointestinal (GI) endoscopy was performed, revealing a circumferential lesion extending continuously from 12 cm above the anal verge to the dentate line, with associated stenosis. The lesion was extensively ulcerated with some areas covered with grey necrotic tissue (Fig. 3). The histopathological analysis of the rectal biopsies revealed lymphocyte infiltration in all layers of the rectal wall (Fig. 4a). In the immunohistochemical staining, cells were immunoreactive for CD20, CD10, bcl-6 and c-myc; the Ki67 immunohistochemical stain depicted 100% proliferative index (Fig. 4b). Detection of EBV by in situ hybridization to EBV-encoded RNA was also positive (Fig. 4c). Fluorescence in situ hybridiza-

tion analysis revealed positive C-MYC gene rearrangement in 80% of analysed nuclei. Based on these findings, the diagnosis of a high-grade non-Hodgkin lymphoma (NHL) – DLBCL type was considered. After a lymphoma-negative bone marrow biopsy infiltration and negative neck and thorax CT scan, needed to complete adequate staging, the final diagnosis of primary rectal NHL DLBCL stage IV was established, and chemotherapy with R-CHOP (rituximab, cyclophosphamide, doxorubicin, vincristine, prednisone) and high-dose methotrexate was started. Colonoscopy evaluation after 6 cycles of chemotherapy revealed complete endoscopic remission (Fig. 5). In the last follow-up visit (November 2021), 4 months after treatment, the patient remains in complete remission, for both the NHL DLBCL and UC.

## Discussion/Conclusion

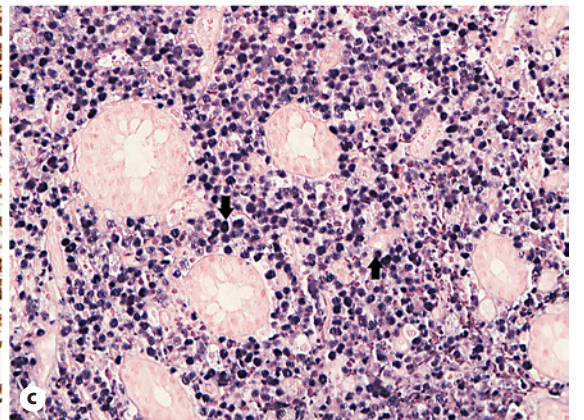
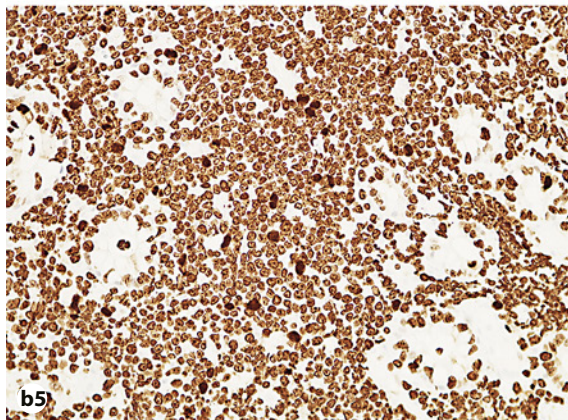
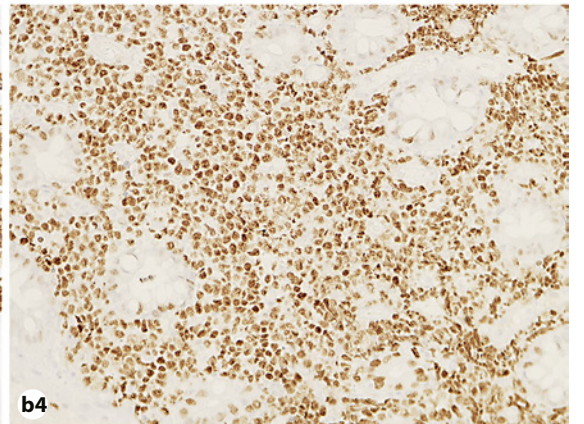
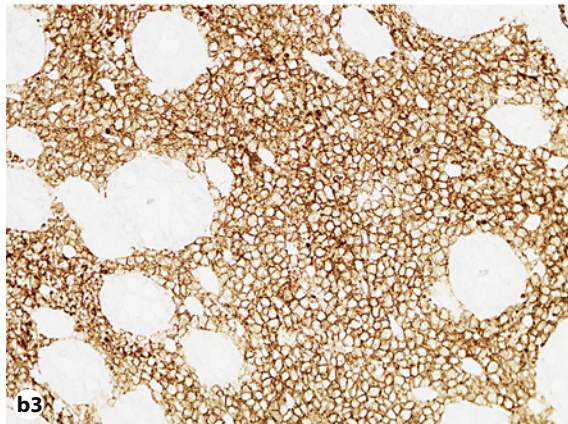
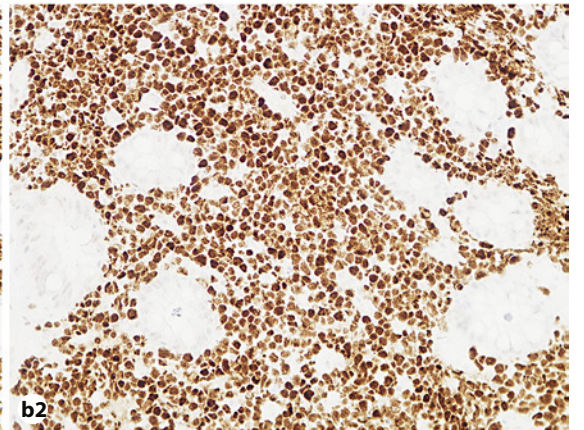
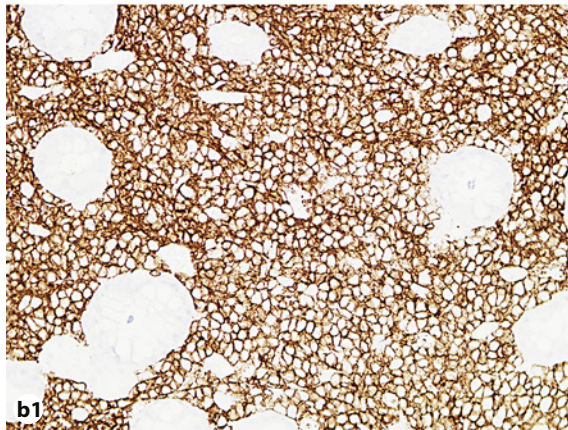
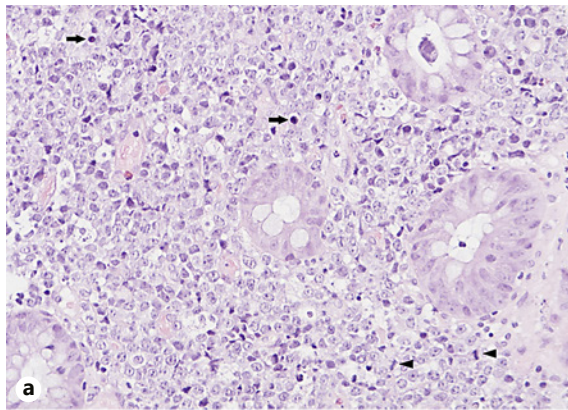
The GI tract is the major site of extranodal NHL and accounts for 30–40% of all cases [2]. While secondary GI involvement is relatively common, primary GI lymphomas are rare, representing only 1–4% of malignancies arising in the GI tract [3, 5]. They are generally defined as lymphomas that predominantly involve any section of the GI tract, in the absence of evidence of systemic disease [6]. They have unique clinical aspects and management considerations [2].

The most common site of primary GI lymphomas is the stomach (50–60%), followed by the small intestine (20–30%) [5, 7]. Involvement of the colon is rare (10–20%), with the cecum being the segment most commonly affected. Primary rectal lymphoma is the rarest location of lymphomas, accounting for 0.05% of all primary rectal malignancies [8].

Primary colorectal lymphomas have a male predominance, with men being twice more often affected than women. It usually occurs in the sixth to seventh decade and presents with abdominal pain, weight loss or changing in bowel habits [2, 3]. Less frequently described symptoms include lower GI bleeding (20% of patients) and obstruction, which occurs less often than in colorectal adenocarcinoma [3, 7].

Among the different histological subtypes of primary colorectal lymphomas, DLBCL is the most common [5, 7, 9], being generally aggressive. Thus, prognosis is poor with a 5-year survival rate of 27–33% [10].

Specific risk factors for primary colorectal lymphomas are largely unknown. However, it is generally assumed that the established risk factors for NHL will also increase the risk for primary colorectal lymphoma. Viral infections (namely HIV, HCV, HBV and EBV), immunosuppressive medications, organ transplantation, family history of lymphoma and personal history of chemo- and/or

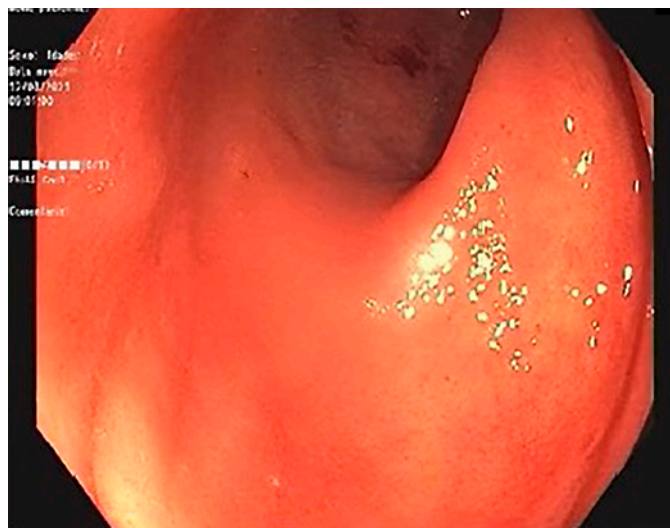


4

(For legend see next page.)

radiotherapy are the main risk factors described in the literature [2]. Some chronic systemic diseases such as autoimmune and immunodeficiency disorders are intrinsically associated with an increased risk of LDs [2, 4]. Contrarily, according to some studies, IBD on its own does not seem to increase the risk for primary colorectal lymphoma [4, 11]. However, when IBD patients are exposed to immunosuppressive therapy, the risk increases significantly. Thiopurines and, to a lesser extent, anti-tumour necrosis factor agents are the drugs associated with excess risk of lymphomas [11]. This LD is often EBV-associated. While the virus promotes malignant transformation, immunosuppressive therapy inhibits the immune system's ability to detect and clear malignant cells [4]. In fact, in the CESAME cohort, the risk of LD was highest in those exposed to thiopurines, with a four- to sixfold increase in risk, and 46% of cases were EBV positive [4, 11].

In the present case, however, primary rectal DLBCL developed in the absence of previous or current immunomodulatory therapy for the treatment of UC. Although



**Fig. 5.** Complete endoscopic remission after treatment.

**Fig. 4.** Rectal biopsies. **a** Infiltration of the rectal wall by lymphoid cells, where mitotic figures (arrowheads) and apoptotic cells (arrows) are easily recognized. Haematoxylin and eosin stain. Magnification  $\times 400$ . **b1–5** Immunohistochemical examination: atypical lymphocytes are CD20, CD10, bcl-6 and c-myc positive with Ki67 immunohistochemical stain depicting 100% proliferative index. **c** Detection of EBV by in situ hybridization to EBV-encoded RNA was positive (blue staining) in the tumor cell nuclei (arrows). Magnification  $\times 400$ .

being extremely rare, similar cases have been reported in the literature [10, 12, 13], raising the hypothesis of alternative mechanisms contributing to the development of DLBCL in UC patients [10]. One of the possible mechanisms is overstimulation of the immune system secondary to chronic colorectal inflammation. In fact, previous studies have suggested that extensive or long-standing IBD seems to be associated with the development of lymphomas in IBD patients, with the mean time between the diagnosis of UC and lymphoma being 12 years [10, 14]. Moreover, lymphoma usually develops in areas affected by intense inflammation.

The underlying possible mechanism is chronic inflammation leading to clonal lymphocyte activation and subsequent proliferation. The maintained lymphocyte stimulation increases the possibility of mutations with consequent development of malignant lymphoma [14]. Additionally, EBV infection may also play a role in the development of lymphoma in long-standing IBD patients, even in the absence of immunosuppressive therapy. Thus, chronic local inflammation may induce a localized immunodepression, favouring the clonal proliferation of EBV-infected B cells [4, 15].

In our case, although the DLBCL developed in a time interval (7 years) that was shorter than that usually reported in the literature, chronic local inflammation may have triggered clonal proliferation of EBV-positive lymphocytes. Although the previous status of EBV infection of our patient is not known, the most probable scenario is the reactivation of a latent EBV infection. Critical association of EBV-associated lymphoproliferative diseases with viral latency and contribution of specific latent antigens to B-cell transformation has been described [16].

In the present case, the clinical presentation mimicking an acute flare of UC and the absence of rectal mucosal lesions in the endoscopic evaluation performed 1 year before posed a diagnostic challenge, highlighting the complexity behind the management of UC patients. This case report emphasizes that, although being rare, the occurrence of colorectal lymphoma should be taken into consideration in UC patients presenting with refractory disease, even when there is no history of previous exposure to immunomodulatory agents, to ensure proper diagnosis and treatment.

### Acknowledgement

The authors would like to thank Dr. Tiago Oliveira and Dr. Cristina Ferreira from the Pathology Department for providing the histological images.

---

## Statement of Ethics

All rules of the local Ethics Committee (Comissão de Ética do Centro Hospitalar Universitário de Lisboa Norte/Centro Académico de Medicina de Lisboa) were followed, preserving patient identity and confidentiality. Informed consent was obtained from the patient for the publication of his case (including publication of images).

---

## Conflict of Interest Statement

The authors have no conflicts of interest to declare.

---

## References

- 1 Hangge PT, Calderon E, Habermann EB, Glasgow AE, Mishra N. Primary colorectal lymphoma: institutional experience and review of a national database. *Dis Colon Rectum*. 2019 Oct;62(10):1167–76.
- 2 Gay ND, Chen A, Okada CY. Colorectal lymphoma: a review. *Clin Colon Rectal Surg*. 2018 Sep;31(5):309–16.
- 3 Ghimire P, Wu GY, Zhu L. Primary gastrointestinal lymphoma. *World J Gastroenterol*. 2011 Feb;17(6):697–707.
- 4 Sokol H, Beaugerie L, Maynadié M, Laharie D, Dupas JL, Flourié B, et al.; CESAME Study Group. Excess primary intestinal lymphoproliferative disorders in patients with inflammatory bowel disease. *Inflamm Bowel Dis*. 2012 Nov;18(11):2063–71.
- 5 Stanojevic GZ, Nestorovic MD, Brankovic BR, Stojanovic MP, Jovanovic MM, Radokovic MD. Primary colorectal lymphoma: an overview. *World J Gastrointest Oncol*. 2011 Jan;3(1):14–8.
- 6 Dawson IM, Cornes JS, Morson BC. Primary malignant lymphoid tumours of the intestinal tract. Report of 37 cases with a study of factors influencing prognosis. *Br J Surg*. 1961 Jul;49:80–9.
- 7 Quayle FJ, Lowney JK. Colorectal lymphoma. *Clin Colon Rectal Surg*. 2006 May;19(2):49–53.
- 8 Jiang C, Gu L, Luo M, Xu Q, Zhou H. Primary rectal lymphoma: a case report and literature review. *Oncol Lett*. 2015 Jul;10(1):43–4.
- 9 Chen Y, Chen Y, Chen S, Wu L, Xu L, Lian G, et al. Primary gastrointestinal lymphoma: a retrospective multicenter clinical study of 415 cases in Chinese province of Guangdong and a systematic review containing 5,075 Chinese patients. *Medicine*. 2015 Nov;94(47):e2119.
- 10 Mansour R, Beattie M, Miller J, Haus C. Diffuse large B-cell lymphoma mimicking an ulcerative colitis flare. *ACG Case Rep J*. 2019 Mar;6(3):1–3.
- 11 Subramaniam K, D’Rozario J, Pavli P. Lymphoma and other lymphoproliferative disorders in inflammatory bowel disease: a review. *J Gastroenterol Hepatol*. 2013 Jan;28(1):24–30.
- 12 Suzuki T, Iwamoto K, Nozaki R, Saiki Y, Tanaka M, Fukunaga M, et al. Diffuse large B-cell lymphoma originating from the rectum and diagnosed after rectal perforation during the treatment of ulcerative colitis: a case report. *BMC Surg*. 2021 Jan 21;21(1):50.
- 13 Marín García D, Cárdenas Lafuente F, Utrilla Ayala Mdel C, Galán Jurado MV, Jiménez Martín JJ, García Ordóñez MA. Linfoma de tipo B difuso de células grandes primario rectal que simula un adenocarcinoma de recto [Primary diffuse large B-cell lymphoma of the rectum simulating a rectal adenocarcinoma]. *Gastroenterol Hepatol*. 2010 Feb;33(2):92–8.
- 14 Watanabe N, Sugimoto N, Matsushita A, Maeda A, Nagai K, Hanioka K, et al. Association of intestinal malignant lymphoma and ulcerative colitis. *Intern Med*. 2003 Dec;42(12):1183–7.
- 15 Copie-Bergman C, Niedobitek G, Mangham DC, Selves J, Baloch K, Diss TC, et al. Epstein-Barr virus in B-cell lymphomas associated with chronic suppurative inflammation. *J Pathol*. 1997 Nov;183(3):287–92.
- 16 Saha A, Robertson ES. Epstein-Barr virus-associated B-cell lymphomas: pathogenesis and clinical outcomes. *Clin Cancer Res*. 2011 May;17(10):3056–63.

---

## Funding Sources

There was no funding.

---

## Author Contributions

S.S. conceptualized and wrote the original draft. S.B., S.M., and L.C. revised the manuscript critically. All the authors read and approved the final paper.