

CLINICAL CASE

Successful closure of unusual tuberculous esophagomediastinal fistula with endoscopic clips

Andreia Albuquerque*, Amadeu Corte-Real Nunes, Fernando Azevedo, Guilherme Macedo

Gastroenterology Department, Centro Hospitalar de S. João, Porto, Portugal

Received 19 January 2013; accepted 14 April 2013
Available online 16 July 2013

KEYWORDS

Tuberculosis;
Esophagomediastinal
fistula;
Endoscopic clips

Abstract A 41-year-old man, on tuberculostatic treatment for three months for disseminated tuberculosis, developed a tuberculous esophagomediastinal fistula, which was successfully closed with endoscopic clips. Use of endoscopic clips in esophageal perforations and closure of fistulas following surgical complications has been described, but to our knowledge there are no previous reported cases of tuberculous esophagomediastinal fistulas managed with clipping. In this case, endoscopic clips associated with tuberculostatic treatment were crucial allowing fistula closure in a symptomatic patient.

© 2013 Sociedade Portuguesa de Gastroenterologia Published by Elsevier España, S.L. All rights reserved.

PALAVRAS CHAVE

Tuberculose;
Fístula
esofagomediastínica;
Endoclips

Utilização de endoclips para o encerramento de fistula esofagomediastínica secundária a tuberculose

Resumo Homem de 41 anos, com tuberculose disseminada sob terapêutica antibacilar há 3 meses, foi submetido a endoscopia digestiva alta que revelou fistula esofagomediastínica secundária a tuberculose. Foi feito o encerramento com sucesso utilizando endoclips. Está descrita a utilização de endoclips em perfurações esofágicas e encerramento de fístulas após complicações cirúrgicas mas, até à data, não foram descritos casos de fístulas esofagomediastínicas secundárias a tuberculose encerradas com endoclips. Esta terapêutica teve um papel adjuvante importante na abordagem deste doente, possibilitando o rápido encerramento e controlo sintomático.

© 2013 Sociedade Portuguesa de Gastroenterologia. Publicado por Elsevier España, S.L. Todos os direitos reservados.

* Corresponding author.

E-mail address: a.albuquerque.dias@gmail.com (A. Albuquerque).

Case report

A 41-year-old man, HIV negative with disseminated tuberculosis was on tuberculostatic treatment for three months. Therapy included isoniazid, rifampicin, ethambutol and pyrazinamide and after 2 months, therapy was resumed to isoniazid and rifampicin. Anti-tuberculosis drug susceptibility testing did not show resistance to antituberculous therapy.

Upper endoscopy was performed due to dysphagia and sporadic coughing and revealed two ulcers with clean bases in the middle third of the esophagus, with 10 mm and 15 mm, this one with a small orifice with the emission of air bubbles from its base (Fig. 1). Biopsies were taken and histological examination revealed esophagitis with accentuated signs of activity and extensive ulceration. Ziehl-Neelsen stain was negative. Immunohistochemical examination was also performed and was negative for cytomegalovirus and herpes virus I and II. The double contrast upper gastrointestinal series and thoracic computed tomography (CT) scan confirmed the presence of an esophagomediastinal fistula (Fig. 2), with the mediastinal ending in contact with an adenopathy.

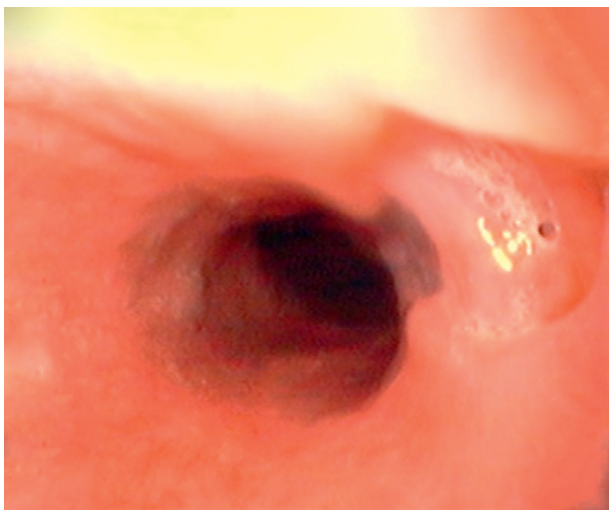


Figure 1 Upper GI endoscopy showing esophageal ulcer with a fistula orifice.

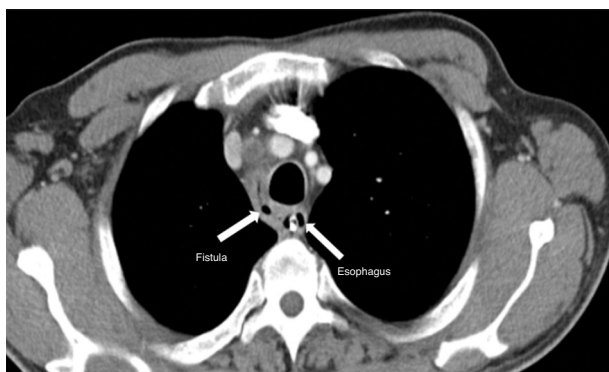


Figure 2 Thoracic CT scan revealing an esophagomediastinal fistula.

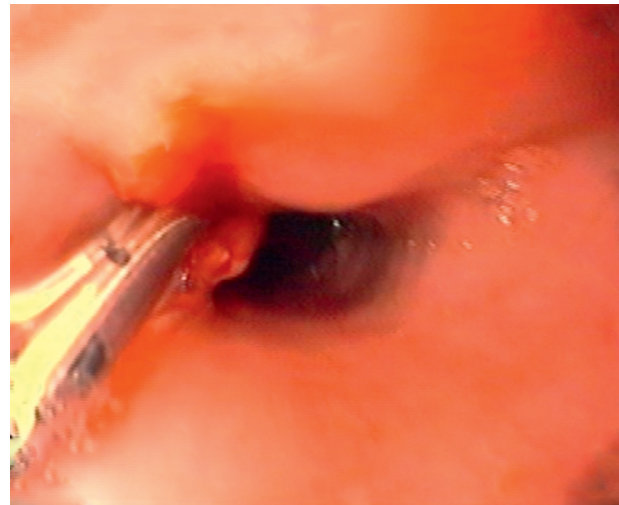

Figure 3 Upper GI endoscopy revealing fistula closure with endoscopic clips.

The decision was made to place endoscopic clips (Resolution Clips Boston Scientific®) for fistula orifice closure (Fig. 3). Four days later an upper endoscopy was repeated and another clip placed on the largest esophageal ulcer to promote fistula closure. On the eleventh day, endoscopic and radiologic closure of the fistula was confirmed (Fig. 4). The patient remained asymptomatic and resumed oral nutrition after closure confirmation. Two months later, there was no evidence of esophagomediastinal fistula, with one clip remaining. After six months, there were only discrete signs of healing.

Discussion

Esophageal involvement in tuberculosis is rare^{1,2} in both immunocompetent and immunocompromised hosts² and is almost always associated with mediastinal lymphadenopathy. The esophagus is the organ least likely to be infected by tuberculosis.¹

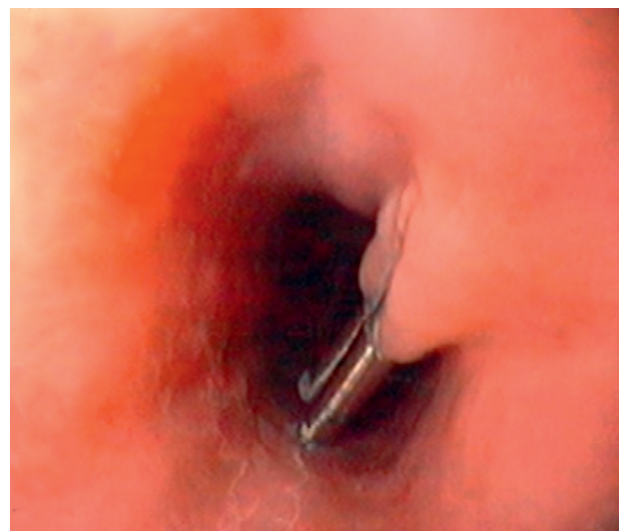

Figure 4 Upper GI endoscopy performed on day eleven showing successful fistula closure with two clips.

Esophagomediastinal fistula has been rarely reported even in patients with tuberculous esophagitis.³ Tuberculous esophagomediastinal fistulas are mainly located in the middle third of the esophagus and have inconspicuous symptoms. Typically there are scarce complications, among which gastrointestinal bleeding is the most significant, usually with a favorable course under medical management alone.⁴

Although in most cases of fistula, surgery is required, there are, however, a number of reports in the literature of endoscopic methods of attempting fistula closure: the application of fibrin glue, use of covered esophageal stents, and clipping have been described.⁵ Endoscopic clips have been widely used in recent years, associated with their growing availability and the simplification of this technique.⁶ They are routinely used for hemostasis in ulcers with visible vessel, Mallory-Weiss, or in complications from polypectomies. Reports of their use in esophageal perforations^{7,8} and closure of esophagomediastinal, tracheal or bronchial fistulas following surgical complications have been described.⁹

Treatment of tuberculous esophagomediastinal fistula is primarily pharmacologic^{1,3} but, our patient was already on tuberculous therapy for 3 months without closure and maintained symptoms. Endoscopic clips proved to be an excellent option for the closure of these small fistulas, allowing closure eleven days following the first endoscopic procedure. The placement of an esophageal prosthesis was considered, but due to the very small fistula orifice diameter (only 2–3 mm) and the possibility of prosthesis migration, the decision was made to place endoscopic clips, been this also a less expensive option.

A paper published by Freeman et al.¹⁰ revealed the factors that significantly reduce the effectiveness of esophageal stent placement for the treatment of esophageal perforation, fistula, or anastomotic leak, namely esophageal leak of the proximal cervical esophagus, an esophageal injury longer than 6 cm or an anastomotic leak associated with a more distal conduit leak.

Endoscopic clips should be considered to promote fistula closure in the presence of a singular, small orifice, been also a less expensive option.

Ethical disclosures

Protection of human and animal subjects. The authors declare that no experiments were performed on humans or animals for this study.

Confidentiality of data. The authors declare that they have followed the protocols of their work center on the publication of patient data and that all the patients included in the study received sufficient information and gave their written informed consent to participate in the study.

Right to privacy and informed consent. The authors declare that no patient data appear in this article.

Conflicts of interest

The authors have no conflicts of interest to declare.

References

1. Devarbhavi HC, Alvares JF, Radhikadevi M. Esophageal tuberculosis associated with esophagotracheal or esophagomediastinal fistula: report of 10 cases. *Gastrointest Endosc.* 2003;57:588–92.
2. Jain SK, Jain S, Jain M, Yaduvanshi A. Esophageal tuberculosis: is it so rare? Report of 12 cases and review of the literature. *Am J Gastroenterol.* 2002;97:287–91.
3. Ohtake M, Saito H, Okuno M, Yamamoto S, Ohgimi T. Esophagomediastinal fistula as a complication of tuberculous mediastinal lymphadenitis. *Intern Med.* 1996;35:984–6.
4. Manigaud G, Grateau G, Dumas D, Fritsch J, Faux N. Esophageal fistulas in mediastinal tuberculous adenopathies in adults. *Sem Hop.* 1983;59:1766–8.
5. Luigiano C, Ferrara F, Polifemo AM, Fabbri C, Ghersi S, Bassi M, et al. Endoscopic closure of esophageal fistula using a novel “clip and loop” method. *Endoscopy.* 2009;41:E249–50.
6. Chuttani R, Barkun A, Carpenter S, Chotiprasidhi P, Ginsberg GG, Hussain N, et al. Endoscopic clip application devices. *Gastrointest Endosc.* 2006;63:746–50.
7. Qadeer MA, Dumot JA, Vargo JJ, Lopez AR, Rice TW. Endoscopic clips for closing esophageal perforations: case report and pooled analyses. *Gastrointest Endosc.* 2007;66:605–11.
8. Raymer GS, Sadana A, Campbell DB, Rowe WA. Endoscopic clip application as an adjunct to closure of mature esophageal perforation with fistulae. *Clin Gastroenterol Hepatol.* 2003;1:44–50.
9. Mizobuchi S, Kuge K, Maeda H, Matsumoto Y, Yamamoto M, Sasaguri S. Endoscopic clip application for closure of an esophagomediastinal-tracheal fistula after esophageal cancer. *Gastrointest Endosc.* 2003;57:962–5.
10. Freeman RK, Ascoti AJ, Giannini T, Mahidhara RJ. Analysis of unsuccessful esophageal stent placements for esophageal perforation, fistula, or anastomotic leak. *Ann Thorac Surg.* 2012;94:959–64.