

CLINICAL CASE

Fulminant hepatitis E in a pregnant woman

Mónica Velosa^{a,b,*}, António Figueiredo^c, Helena Glória^b, Ana Morbey^b,
Elia Mateus^b, Zélia Neves^d, Ana Araújo^d, Ana Carvalho^c,
Judite Oliveira^d, Eduardo Barroso^b

^a Serviço de Gastreenterologia, Hospital Central do Funchal, Funchal, Portugal

^b Unidade de Transplantação, Hospital Lisboa Central – Curry Cabral, Lisboa, Portugal

^c Serviço de Anatomia Patológica, Hospital Lisboa Central – Curry Cabral, Lisboa, Portugal

^d Unidade de Cuidados Intensivos, Hospital Lisboa Central – Curry Cabral, Lisboa, Portugal

Received 17 October 2012; accepted 29 April 2013

Available online 5 October 2013

KEYWORDS

Hepatitis E virus;
Liver transplant;
Fulminant hepatitis;
Pregnancy

Abstract Hepatitis E is an inflammatory liver disease caused by hepatitis E virus (HEV) infection, which is endemic in China, India, Nepal, and in several Asian and African countries, where the prevalence can be as high as 50%. In non-endemic countries, an increasing number of non-travel associated HEV has been reported in recent years, particularly in Europe.

The authors describe the clinical case of a puerperal 24-year-old woman from Pakistan admitted to our Tertiary Care Medical Center with acute hepatic failure developed during the third trimester of her pregnancy. She was icteric with grade III encephalopathy and hypothermia. Laboratory values showed significant AST, ALT and LDH elevations of twelve times the upper normal limit, and total bilirubin was significantly elevated (41.20 mg/dL). Prothrombin time was prolonged (4s) and factor V activity was diminished (15.1%). Extracorporeal albumin dialysis was initiated, but clinical deterioration occurred within 48h, so she underwent OLT at day 4 post-admission.

Severe forms of HEV are known to be more pronounced in pregnant women. Even though most of the described cases of acute hepatic failure associated to HEV during pregnancy had a favorable clinical course, some cases of fulminant liver failure and death are described. It is unknown whether liver transplant outcomes in this setting are different from other causes of acute liver failure. To our knowledge, this is the first case report in Portugal from a pregnant woman who developed hepatic failure due to fulminant hepatitis E that underwent successful liver transplantation.

© 2012 Sociedade Portuguesa de Gastreenterologia Published by Elsevier España, S.L. All rights reserved.

* Corresponding author.

E-mail address: mo.velosa@gmail.com (M. Velosa).

PALAVRAS-CHAVE

Vírus da hepatite E;
Transplante hepático;
Hepatite Fulminante;
Gravidez

Hepatite E fulminante numa mulher grávida

Resumo A Hepatite E é uma doença inflamatória do fígado causada pelo Vírus da Hepatite E (VHE). Este vírus é endêmico na China, Nepal, Índia e em vários países Africanos e Asiáticos, onde a sua prevalência pode atingir os 50%. Em países não endêmicos, particularmente na Europa, tem-se verificado um aumento da prevalência de VHE não associada a viagens.

Os autores descrevem o caso de uma doente de 24 anos, puérpera, natural do Paquistão, admitida no nosso Centro Terciário com insuficiência hepática aguda, com início no terceiro trimestre da gravidez. A doente encontrava-se icterica, com encefalopatia hepática grau III e hipotermia. Os valores laboratoriais mostraram elevação significativa de 12 vezes o limite superior do normal das aminotransferases (AST e ALT) e da LDH, com bilirrubina total elevada (41.2 mg/dL), prolongamento do tempo de protrombina (4 seg) e actividade do factor v diminuída (15.1%). A doente iniciou diálise de albumina extra-corporal, contudo verificou-se rápida deterioração, tendo sido submetida a transplante hepático no 4º dia após a admissão.

Formas mais graves de hepatite associada a VEH têm sido descritas durante a gravidez. Geralmente, mesmo as formas mais graves têm uma evolução tendencialmente favorável, com apenas alguns casos descritos de morte e de hepatite fulminante. Desconhece-se para já qual o resultado a longo prazo dos doentes transplantados por hepatite E fulminante, quando comparados com outras populações. Este caso representa o primeiro caso descrito em Portugal de uma doente grávida com hepatite fulminante causada por VHE, submetida com sucesso a transplante hepático.

© 2012 Sociedade Portuguesa de Gastrenterologia. Publicado por Elsevier España, S.L. Todos os direitos reservados.

Introduction

Hepatitis E is an inflammatory liver disease caused by hepatitis E virus (HEV) infection, which is a single-stranded, non-enveloped RNA virus and the only virus within the genus *Hepevirus* and the family *Hepeviridae*.^{1,2} The first described cases of acute liver disease caused by an enteric infectious agent that differed from hepatitis A and hepatitis B viruses were reported in India in the 1970s.² HEV is endemic in China, India, Nepal, as well as in several Asian and African countries, where the prevalence of HEV IgG antibody can be as high as 50%.³ It has been recently estimated that its infection causes more than 3 million symptomatic cases of acute hepatitis E each year, resulting in approximately 70,000 deaths worldwide.⁴ In non-endemic countries, an increasing number of non-travel associated HEV cases have been reported in recent years, particularly in Europe.^{5,6} In Portugal, sporadic cases have been reported, and a study on 237 individuals, from which 152 were patients from a Gastroenterology Department, showed that 4.2% of the population enrolled was seropositive for anti-HEV. Furthermore, in the seropositive group, only 20% had a history of traveling to endemic countries.⁷

Testing for hepatitis E should be done in the diagnostic analysis of all patients with acute or chronic hepatitis that cannot be explained by other causes. Acute HEV infection is diagnosed in immunocompetent individuals based on the detection of anti-HEV IgM. Immunocompromised individuals should always be tested for HEV RNA, if there is suspicion that they are infected, because seroconversion can be delayed in these patients.^{8,9}

Most infections have a clinically silent course. In symptomatic cases, the incubation period ranges from 2 to 8 weeks, with a mean of 40 days.¹ Initial symptoms of acute hepatitis E are typically unspecific and include flu-like myalgia, arthralgia, weakness and vomiting. However, more

severe forms of acute liver disease can occur in pregnant women or patients with underlying chronic liver diseases, sometimes progressing to fulminant hepatic failure.¹⁰ In immunocompetent patients, HEV is mainly self-limited and causes no chronic evolution. In fact, in these individuals, acute hepatitis E does not usually require therapy.¹¹ Nevertheless, in immunocompromised patients, HEV can pursue a chronic course. Persistent HEV infection was first reported in 2008 in 8 French solid organ transplant recipients on immunosuppression. Furthermore, one kidney-transplant patient had cirrhosis attributed to chronic HEV infection.² HEV-associated liver cirrhosis or hepatocellular carcinoma in the immunocompetent patient has not been reported, so far; however, acute HEV infection is known to be a cause of decompensated liver cirrhosis.¹²

Case report

A 24-year-old puerperal woman was admitted to our Tertiary Care Medical Center with acute hepatic failure. She was a Pakistani woman living in Portugal for 3 years that had recently traveled to Pakistan while pregnant, for a total stay of 3 months. She returned to Portugal during the third trimester of her pregnancy, 3 weeks before admission in our Hospital. During her time in Pakistan, she was observed by an Obstetrician and did a fetal ultrasound that she reported as being normal. She denied having any symptoms while in Pakistan, contact with sick people and/or previous history of hepatitis in her relatives. Her background was unremarkable, she was married and mother of a 2-year-old healthy child, with a regular pregnancy and an eutocic delivery and a history of 2 previous spontaneous abortions. She denied current medication and toxic or alcohol consumption.

During pregnancy week 32, the patient reported nausea, vomiting, asthenia and myalgia. She went to an outpatient Obstetrics Consult in another Institution and in the

same day was referred to the emergency room, because she also had jaundice. She did not recall what happened next. At that point, blood tests showed high liver enzymes (transaminases aspartate transaminase [ALT] and alanine transaminase [ALT]) and hyperbilirubinemia. Labor was induced and she delivered a healthy female baby. During the next 12 h, she developed grade I encephalopathy, therefore being transferred to the ICU of our hospital. Upon admission, examination showed that she was markedly icteric, with grade III encephalopathy (Glasgow Coma Scale: 6). She was hypothermic (34.7°C), hemodynamically stable, without palpable hepatomegaly, and her uterus was palpable 3 cm above her pubic symphysis. Laboratory values upon admission showed significant elevations in AST (406 IU/L [normal, 10–37 UI/L]), ALT (569 IU/L [normal, 10–37 UI/L]), lactate dehydrogenase (1358 [normal, 205–423 UI/L]), alkaline phosphatase 354 UI/L [normal, 44–155 UI/L] and NH₃ 47 ([normal, 8–33 μmol/L]). Bilirubin was significantly elevated (41.20 mg/dL, [normal, 0.4–1.2 mg/dL]), with unconjugated bilirubin of 10.6 mg/dL. Gamma-glutamyl transpeptidase (GGT) was slightly elevated (63 UI/L [normal, 10–49 UI/L]). Arterial lactic acid was elevated (34 mg/dL [normal, 4.5–14.4 mg/dL]). Prothrombin time was prolonged (PT-INR, 5.4 [normal, 0.81–1.38]), and factor v activity was diminished (15.1%). She had a normal platelet count. The head CT scan was normal and the abdominal ultrasound showed normal liver echogenicity without structural abnormalities, with patent, non-occluded liver vasculature. Screening for hepatitis A, B, C and G, syphilis, cytomegalovirus, herpes simplex virus, toxoplasmosis, leptospirosis, antinuclear antibodies (ANA), smooth muscle antibodies (SMA) and antibodies to liver/kidney microsome type 1 (LKM1) were negative. PCR for Hepatitis E RNA was strongly positive, so she was diagnosed with acute hepatic failure caused by acute hepatitis E, with hepatic encephalopathy. She was listed for urgent orthotopic liver transplantation (OLT) and immediately started on extracorporeal albumin dialysis (Prometheus®), but clinical deterioration occurred within 48 h. Given her low Glasgow Coma Scale of 3, mechanical ventilation was required. She underwent OLT at day 4 post-admission. Her explant had no major macroscopic alterations, except a slight softening of its consistency. The histological analysis revealed extensive areas of confluent panlobular, non-zonal necrosis, with porto-portal, porto-central and centro-central bridges. The residual parenchyma showed ballooned hepatocytes, marked pseudo-rosettes formation and cholestasis, either cytoplasmic or in the center of the rosettes (cholestatic rosettes). Lobular inflammation with lymphocytes, plasmacytes, some neutrophils and numerous histiocytes were also detected (Figs. 1–3). Immediate graft function post-transplant was good and she had an unremarkable recovery. Serum Hepatitis E RNA (PCR) was negative 2 months after transplantation.

Genotype analysis, performed in collaboration between Molecular Diagnostic Section, Clinical Microbiology & Public Health Laboratory Addenbrooke's Hospital (Cambridge), UK Reference Laboratory and Microbiology Department, Medical Sciences University (Lisbon) confirmed that the virus is HEV. However, maximal similarity with more than one genotype was observed, meaning that this HEV could be a new genotype.

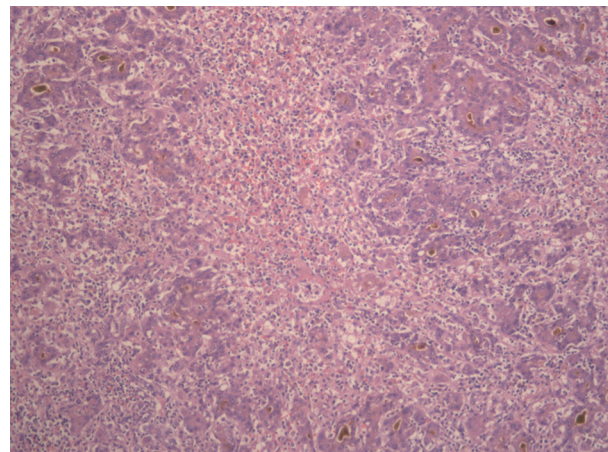


Figure 1 Extensive areas of confluent necrosis and pseudo-rosettes formation (H&E 50×).

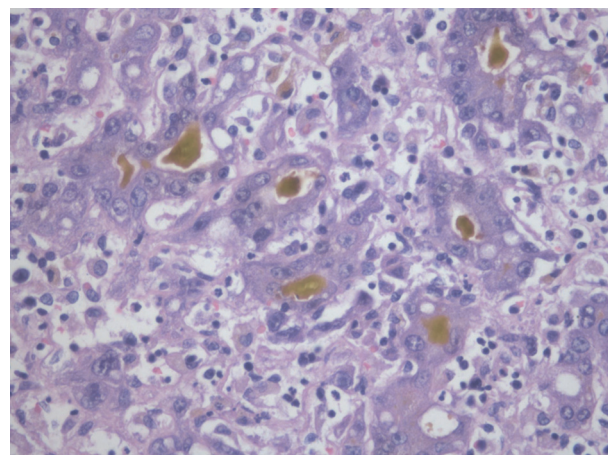


Figure 2 Marked hepatic necrosis with regenerative pseudo-rosette formation. There is cholestasis and moderate mixed inflammatory infiltrate (H&E 400×).

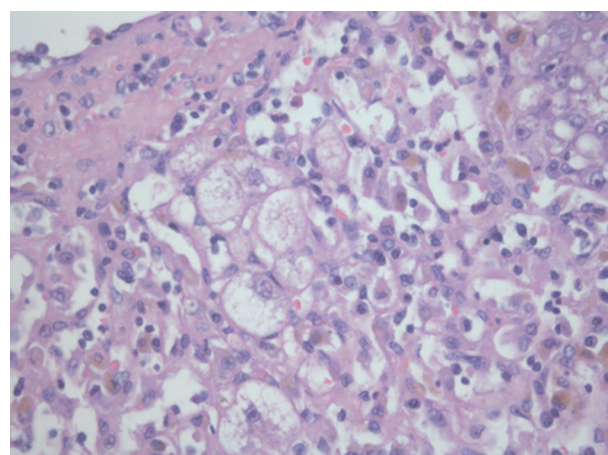


Figure 3 Hepatocyte ballooning (H&E 400×).

The newborn was icteric at birth, with total bilirubin of 14.8 mg/dL and positive IgG anti-HEV and negative IgM anti-HVE. She underwent phototherapy treatment, plus one exchange transfusion, with normalization of total bilirubin.

After 3 weeks at the neonatal ICU, she was transferred to the Pediatric Department, where she was released after 7 weeks.

Discussion

In a general population living in a country where HEV is endemic, mortality associated with fulminant hepatitis is approximately 1%.⁵ These severe forms of HEV are more pronounced in pregnant women, in which mortality can be as high as 20–30%.¹³

There is a complex interaction among viral, host, immunological and hormonal factors, producing a paradigm of severe liver damage in pregnancy. The maternal immune system is clearly altered to tolerate a genetically different fetus.¹⁴ These immunological changes promote the maintenance of the antigenic fetus in the maternal environment by suppression of T-cell-mediated immunity. There is a clear shift in the T-helper type 1 (Th1): Th2 cell paradigm during pregnancy, with a definite skew toward Th2 cells. The levels of most cytokines are depressed, particularly during the initial 20 weeks of pregnancy. CD4 counts are generally lower in HEV positive pregnant patients, while CD8 counts are higher. The ratio of CD4/CD8 in these patients with fulminant hepatic failure was significantly lower when compared to HEV negative patients or controls.¹⁵ Viral load and genotypes have been implicated in the severity of liver disease, and HEV viral load was found to be significantly higher in pregnant when compared to the non-pregnant.¹⁶ Genotype 1 and 4 are the most common subtype causing HEV infection in endemic countries as Pakistan, while genotype 3 predominates in the US. The genotype of this patient is not available yet, and even though there is some speculation regarding the influence of the genotype on clinical features in this setting, that remains to be proven.¹⁶ Furthermore, there are evidences indicating that higher steroid hormone levels, as presented during pregnancy, may influence viral replication.¹⁷ For the time being, although there is no consensus on how to treat patients with HEV infection in pregnancy, early delivery of the fetus, if possible, should be attempted, to prevent maternal mortality.¹⁷

Most of the described cases of acute hepatic failure associated to HEV during pregnancy had a favorable clinical course, but patients developing fulminant liver failure had a higher mortality rate.^{13,18–20} However, a study by Bhatia et al. showed that once fulminant hepatitis appears, the mortality rate might be similar in pregnant women with hepatitis E and in those with other causes of severe liver injury.¹⁰ However, despite this finding, the higher incidence of symptomatic disease and that of FHF among pregnant women exposed to and/or infected with HEV implies that the overall mortality rate among pregnant women is much higher than non-pregnant woman and men during outbreaks of hepatitis E.²¹

Liver transplant is considered an option, but it is unknown whether its outcomes in this setting are different from other causes of acute liver failure. Furthermore, vertically transmitted HEV infection through cord blood is known to cause acute hepatitis in newborn babies. Khuroo et al. studied 19 newborn babies born to HEV infected mothers and showed that 78.9% $n=15$ of those babies had evidence of

vertically transmitted HEV infection at birth. Seven babies died in the first week after birth and all the surviving babies had self-limited disease, while none had prolonged viremia.²²

As the majority of cases are self-limited, liver biopsy is not usually performed, so the histology data about HEV acute hepatitis are scarce. However, several cases of acute HEV in the western world have recently been diagnosed with histological analysis.^{23,25,26} Malcolm et al. assessed liver histology from patients with acute HEV, either locally acquired or imported from endemic areas, and found some differences. The latter leads to spotty or confluent necrosis, portal and lobular inflammation, ballooning degeneration of hepatocytes, intracytoplasmic and intracanalicular cholestasis and hepatocyte pseudo-rosette formation, in accordance with the features of our case.²⁴ On the other hand, sporadic cases show geographical variation of the portal inflammatory infiltrate, with polymorphs at the periphery and interface, while lymphocytes at the center, perivenular edema with hepatocyte loss, aggregates of lipofuscin-containing Kupffer cells, necrosis and fibrosis of zone 3 and no pseudo-rosette formation.²³ However, these differences are not clearly defined and both forms may have cholestatic features.²⁵ These aspects are clearly different from chronic HEV infection in immunocompromised individuals, as they present a dense lymphocytic portal infiltrate, piecemeal necrosis and fibrosis, similar to cases of HCV.²⁶

Agrawal et al. compared the histology of fulminant HEV with fulminant HBV cases and found that interface hepatitis was significantly more frequent in patients with HBV than in those with HEV. Although not reaching statistical significance, ballooning, pseudo-rosette formation, steatosis and plasma cells were more prevalent in HEV. The pseudo-rosettes (a striking feature of our case) are uncommon in the western cases and frequent in the cases in endemic areas.²⁵

The histological aspects of our case are similar to those found by Malcolm et al. and Agrawal et al. in endemic areas, which correlates with the anamnesis. Although the correct diagnosis is a serologic one, it seems there are some histological aspects that can give a clue on the HEV etiology, and even some differences in the endemic/sporadic cases, probably reflecting different genotypes.²⁴

As far as we know, this is the first case report in Portugal from a pregnant woman who developed hepatic failure due to fulminant hepatitis E that underwent a successful liver transplantation.

Ethical disclosures

Protection of human and animal subjects. The authors declare that no experiments were performed on humans or animals for this study.

Confidentiality of data. The authors declare that they have followed the protocols of their work center on the publication of patient data and that all the patients included in the study received sufficient information and gave their written informed consent to participate in the study.

Right to privacy and informed consent. The authors declare that no patient data appear in this article.

Conflicts of interest

The authors have no conflicts of interest to declare.

References

- Purcell RH, Emerson SU. Hepatitis E: an emerging awareness of an old disease. *J Hepatol.* 2008;48:494–503.
- Aggarwall R, Jameel S. Hepatitis E. *Hepatology.* 2011;54:2218–26.
- Taniguchi M, Kim SR, Mishiro S, Takahashi K, Shin MH, Yun H, et al. Epidemiology of hepatitis E in Northeastern China, South Korea and Japan. *J Infect.* 2009;58:232–7.
- Rein DB, Stevens G, Theaker J, Wittenborn JS, Wiersma ST. The global burden of hepatitis E virus. *Hepatology.* 2011 [Epub ahead of print].
- Dalton HR, Bendall R, Ijaz S, Banks M. Hepatitis E: an emerging infection in developed countries. *Lancet Infect Dis.* 2008;8:698–709.
- Lewis HC, Wichmann O, Duizer E. Transmission routes and risk factors for autochthonous hepatitis E virus infection in Europe: a systematic review. *Epidemiol Infect.* 2010;138:145–66.
- Folgado S, Pires S, Félix J, Figueiredo A, Silva L, Franco M, et al. Prevalência da hepatite E em população não endêmica-estudo prospectivo. *GE-J Port Gastreenterol.* 2009;16:191–7.
- Drobeniuc J, Meng J, Reuter G, Greene-Montfort T, Khudyakova, Dimitrova Z, et al. Serologic assays specific to immunoglobulin M antibodies against hepatitis E virus: pangenotypic evaluation of performances. *Clin Infect Dis.* 2010;51:e24–27.
- Pischke S, Suneetha PV, Baechlein C, Barg-Hock H, Heim A, Kamar N, et al. Hepatitis E virus infection as a cause of graft hepatitis in liver transplant recipients. *Liver Transpl.* 2010;16:74–82.
- Bhatia V, Singhal A, Panda SK, Acharya SK. A 20-year single-center experience with acute liver failure during pregnancy: is the prognosis really worse? *Hepatology.* 2008;48:1577–85.
- Mallet V, Louvet A, Lebray P, Hillaire S, Roulot D, Hillom P, et al. Ribavirin treatment for chronic hepatitis E: a case-series. *Hepatology.* 2010;52:919A–1020A.
- Wedemeyer H, Pischke S, Manns M. Pathogenesis and treatment of hepatitis E virus infection. *Gastroenterology.* 2012;142:1388–97.
- Kumar A, Beniwal M, Kar P, Sharma JB, Murthy NS. Hepatitis E in pregnancy. *Int J Gynaecol Obstet.* 2004;85:240–4.
- Navanmeethan U, Al Mohajer M, Shata MT. Hepatitis E and pregnancy: understanding the pathogenesis. *Liver Int.* 2008;28:1190–9.
- Jilani N, Das BC, Husain SA, Baweja UK, Chattopadhyaya D, Gupta RK, et al. Hepatitis E virus infection and fulminant hepatic failure during pregnancy. *J Gastroenterol Hepatol.* 2007;22:676–82.
- Kar P, Jilani N, Husain SA, Pasha ST, Anand R, Rai A, et al. Does hepatitis E viral load and genotypes influence the final outcome of acute liver failure during pregnancy? *Am J Gastroenterol.* 2008;103:2495–501.
- Styrt B, Sugarman B. Estrogens and infection. *Rev Infect Dis.* 1991;13:1139–50.
- Hussaini SH, Skidmorre SJ, Richardson P, Sherratt LM, Cooper BT, O'Grady JG. Severe hepatitis E infection during pregnancy. *J Viral Hepat.* 1997;4:51–4.
- Singh S, Mohanty A, Joshi YK, Dwivedi SN, Deka D. Outcome of hepatitis E virus infection in Indian pregnant woman admitted to a tertiary care hospital. *Indian J Med Res.* 2001;113:35–9.
- Khuroo MS, Kamili S. Aetiology, clinical course and outcome of sporadic acute viral hepatitis in pregnancy. *J Viral Hepat.* 2003;10:61–9.
- Aggrawal R. Clinical presentation of hepatitis E. *Virus Res.* 2011;161:15–22.
- Khuroo MS, Kamili S, Khuroo MS. Clinical course and duration of viremia in vertically transmitted hepatitis E virus (HEV) infection in babies born to HEV-infected mothers. *J Viral Hepat.* 2009;16:519–23.
- Malcom P, Dalton H, Hussaini HS, Mathew J. The histology of acute autochthonous hepatitis E virus infection. *Histopathology.* 2007;51(2):190–4.
- Agrawal V, Goel A, Rawat A, Naik S, Aggarwal R. Histological and immunohistochemical features in fatal acute fulminant hepatitis E. *Indian J Pathol Microbiol.* 2012;55:22–7.
- Peron JM, Danjoux M, Kamar N, Missouri R, Poirson H, Vinel JP, et al. Liver histology in patients with sporadic acute hepatitis E: a study of 11 patients from South-West France. *Virchows Arch.* 2007;450:405–10.
- Selves J, Kamar N, Mansuy JM. Hepatitis E virus: a new entity. *Ann Pathol.* 2010;30:432–8.