

Primary syphilis – an atypical presentation

Sífilis primária – um caso de apresentação clínica atípica

Elisa Soares¹, Pedro Brandão², Ana Torgal³
Centro Hospitalar do Tâmega e Sousa, EPE

Abstract

Syphilis is a sexually transmitted disease caused by the spirochete *Treponema pallidum*. The clinical manifestations of this disease vary widely, according to its stage. Primary syphilis typically presents as a single painless genital ulcer. The authors report a case of an atypical presentation of primary syphilis: multiple vulvar, perianal and between the buttocks ulcerated and very painful papules and plaques, with seropurulent exudate.

Keywords: Primary Syphilis, Vulvar ulcers, *Treponema pallidum*.

Syphilis is a sexually transmitted disease that can represent a great diagnostic challenge. This disease is also known as "the great imitator", due to its variety of possible clinical presentations.

Although primary syphilis typically presents as a single painless genital ulcer, it can become painful if secondarily infected¹. In addition, the presence of multiple lesions may occur, particularly in immunocompromised patients².

Aetiology determination of vulvar ulcers is often hampered, either by the broad spectrum of possible clinical manifestations or by frequent overlapping infections³.

In these cases, it is particularly important to carry out a detailed anamnesis, with thorough evaluation of the sexual history, physical examination, and request of laboratory tests, allowing the establishment of a differential diagnosis among the different causes of vulvar ulcers.

The authors report a case of 43-year-old women, 3G3P, without relevant medical history, and history of penicillin allergy, who went to the general emergency department with multiple painful vesicular vulvar lesions. Due to clinical suspicion of genital herpes, she

was medicated with acyclovir.

A month later, due to the worsening of the lesions, she returned to the emergency department and was observed by a gynaecologist.

A thorough anamnesis revealed non-compliance with previously prescribed therapeutic plan and sexual risk behaviors.

Physical examination revealed multiple vulvar, perianal and between the buttocks ulcerated, and very painful plaques and papules, with seropurulent exudate (which was collected for cultural exam), and one umbilical papular lesion (Figure 1). There were no vaginal lesions or inguinal adenopathies.

Cultural exam of lesion exudate was positive for *Staphylococcus aureus* and *Methicillin-sensitive Streptococcus agalactiae*. PCR for HSV 2 in the lesions swab came positive, and for HSV 1 came negative.

Serological results were as follows: positive anti-HCV antibody, negative HIV 1 and 2 antibodies and positive VDRL (1:84).

Given these clinical manifestations and analytic findings, syphilis was the main hypothesis of diagnosis. However, FTA-abs test was negative. Despite this, the presence of *T. pallidum* in the exudate of the lesions was verified at darkfield microscopy.

As a first approach, treatment with 500 mg/day intravenous erythromycin was started empirically. Seven days after, given the presence of *T. pallidum* in the lesions and the history of penicillin allergy (standard therapy for primary syphilis⁴) the patient was treated

1. Ginecologia e Obstetrícia, Interna de Formação Específica, Centro Hospitalar Tâmega e Sousa

2. Ginecologia e Obstetrícia, Assistente Hospitalar, Instituto Valenciano de Infertilidad (IVI) - Valência, Espanha

3. Ginecologia e Obstetrícia, Assistente Hospitalar Graduada, Centro Hospitalar Tâmega e Sousa

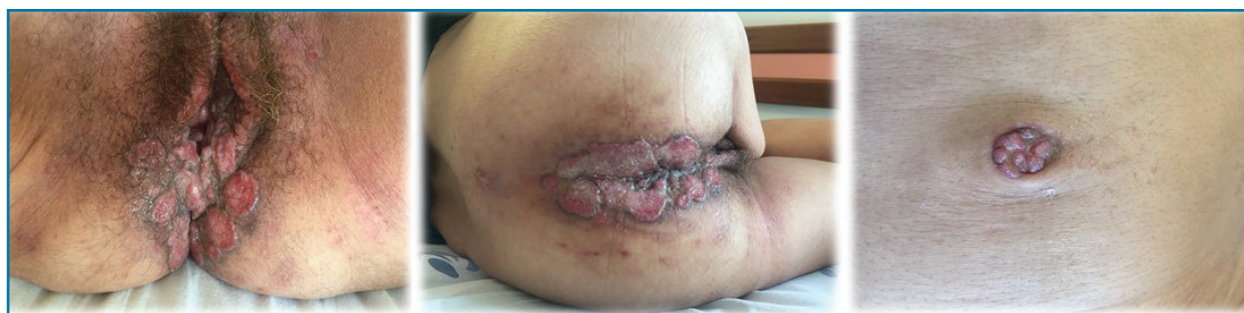

FIGURE 1. Vulvar, perianal, between the buttocks and umbilical lesions

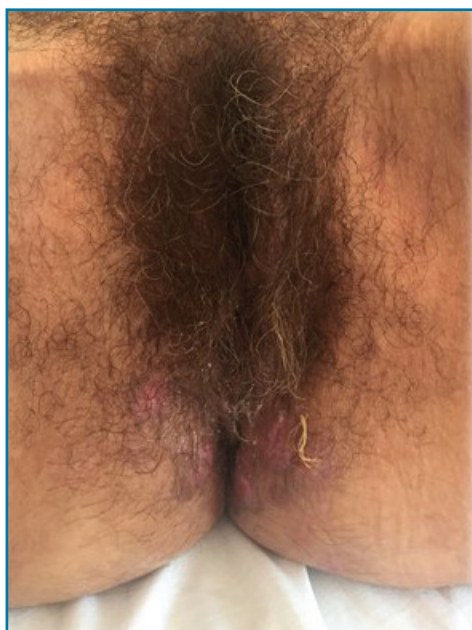


FIGURE 2. Perineum after treatment

with doxycycline 100 mg/day *per os* during 14 days.

At the time of discharge, significant clinical improvement was observed with erythematous plaques, without exudate, ulceration or pain (Figure 2).

One month after discharge, FTA-abs came positive, supporting the diagnosis of syphilis.

REFERÊNCIAS

1. Janier M , Hegyi V, Dupin N, Unemo M , Tiplica GS , Poto nik M , French P , Patel R. 2014 European Guideline on the Management of Syphilis.
2. French P. Syphilis. BMJ. 2007;334(7585):143.
3. Rosen T, Brown TJ. Genital ulcers. Evaluation and treatment. Dermatol Clin. 1998;16(4):673.
4. WHO GUIDELINES FOR THE Treatment of *Treponema pallidum* (syphilis). World Health Organization; 2016.

ENDEREÇO PARA CORRESPONDÊNCIA

Elisa Sofia Oliveira Soares
Centro Hospitalar Tâmega e Sousa, Penafiel, Porto
E-Mail: elisa.s.o.soares@gmail.com

RECEBIDO EM: 09/08/2019

ACEITE PARA PUBLICAÇÃO: 18/05/2020